

PEDIATRICS®

OFFICIAL JOURNAL OF THE AMERICAN ACADEMY OF PEDIATRICS

Neonatal Cranial Ultrasound Lesions and Developmental Delays at 2 Years of Age Among Extremely Low Gestational Age Children

T. Michael O'Shea, Karl C. K. Kuban, Elizabeth N. Allred, Nigel Paneth, Marcello Pagano, Olaf Dammann, Lisa Bostic, Kara Brooklier, Samantha Butler, Donald J. Goldstein, Gail Hounshell, Cecelia Keller, Susan McQuiston, Alice Miller, Steve Pasternak, Susan Plesha-Troyke, Joan Price, Elaine Romano, Katherine M. Solomon, Amanda Jacobson, Sjirk Westra and Alan Leviton

Pediatrics 2008;122:e662

DOI: 10.1542/peds.2008-0594

The online version of this article, along with updated information and services, is located on the World Wide Web at:

<http://pediatrics.aappublications.org/content/122/3/e662.full.html>

PEDIATRICS is the official journal of the American Academy of Pediatrics. A monthly publication, it has been published continuously since 1948. PEDIATRICS is owned, published, and trademarked by the American Academy of Pediatrics, 141 Northwest Point Boulevard, Elk Grove Village, Illinois, 60007. Copyright © 2008 by the American Academy of Pediatrics. All rights reserved. Print ISSN: 0031-4005. Online ISSN: 1098-4275.

American Academy of Pediatrics

DEDICATED TO THE HEALTH OF ALL CHILDREN™



Neonatal Cranial Ultrasound Lesions and Developmental Delays at 2 Years of Age Among Extremely Low Gestational Age Children

T. Michael O'Shea, MD, MPH^a, Karl C. K. Kuban, MD, SMEpi^b, Elizabeth N. Allred, MS^{c,d}, Nigel Paneth, MD, MPH^e, Marcello Pagano, PhD^d, Olaf Dammann, MD^f, Lisa Bostic, OTR/L^g, Kara Brooklier, PhD^h, Samantha Butler, PhDⁱ, Donald J. Goldstein, PhD^a, Gail Hounshell, PhD^a, Cecelia Keller, PT, MHA^f, Susan McQuiston, PhD^j, Alice Miller, PT, MS^k, Steve Pasternak, PhD^l, Susan Plesha-Troyke, OT^m, Joan Price, EdSⁿ, Elaine Romano, MSN^o, Katherine M. Solomon, PhD^h, Amanda Jacobson, PT^q, Sjikr Westra, MD^p, Alan Leviton, MD, MS^c, for the Extremely Low Gestational Age Newborns Study Investigators

^aDepartment of Pediatrics, Wake Forest University, Winston-Salem, North Carolina; ^bDivision of Pediatric Neurology, Department of Pediatrics, Boston Medical Center, Boston University, Boston, Massachusetts; ^cNeuroepidemiology Unit, Department of Neurology, Children's Hospital Boston, Harvard University, Boston, Massachusetts; ^dDepartment of Biostatistics, Harvard School of Public Health, Harvard University, Boston, Massachusetts; ^eDepartment of Epidemiology, Michigan State University, East Lansing, Michigan; ^fDivision of Newborn Medicine, Floating Hospital for Children at Tufts Medical Center, Boston, Massachusetts; ^gDepartment of Occupational Therapy, University of North Carolina, Chapel Hill, North Carolina; ^hCenter for Human Development, William Beaumont Hospital, Royal Oak, Michigan; ⁱDepartment of Psychiatry, Children's Hospital, Boston, Massachusetts; ^jBaystate Medical Center, Springfield, Massachusetts; ^kDepartment of Pediatrics, University of Massachusetts-Memorial Health Center, Worcester, Massachusetts; ^lPediatric Psychology, DeVos Children's Hospital, Grand Rapids, Michigan; ^mDepartment of Pediatrics, University of Chicago, Chicago, Illinois; ⁿEarly Childhood Services/Referrals, Michigan State University-Sparrow Medical Center, Lansing, Michigan; ^oYale University Medical Center, New Haven, Connecticut; ^pDepartment of Pediatric Radiology, Massachusetts General Hospital, Harvard Medical School, Boston, Massachusetts

The authors have indicated they have no financial relationships relevant to this article to disclose.

What's Known on This Subject

In low birth weight and preterm newborns, cranial ultrasound abnormalities indicative of white matter damage are the strongest predictors of cerebral palsy and developmental delays.

What This Study Adds

The association of cerebral white matter damage and developmental impairments applies to extremely low gestational age newborns. The association is stronger for motor, as compared with mental, development. Cerebellar hemorrhage is strongly associated with delayed mental and motor development.

ABSTRACT

BACKGROUND. Studies of the relationship between ultrasound images from preterm newborns and developmental delay most often are based on small samples defined by birth weight and exclude infants not testable with standardized assessments.

METHODS. We evaluated associations between ultrasound-defined lesions of the brain and developmental delays at 24 months' corrected age in 1017 children born before the 28th postmenstrual week. Brain ultrasound scans were read for concordance on 4 lesions: intraventricular hemorrhage, moderate/severe ventriculomegaly, white matter echodense/hyperechoic lesions, and white matter echodense/hypoechoic lesions and 2 diagnoses—periventricular leukomalacia and periventricular hemorrhagic infarction. Certified examiners, who were not aware of the infants' ultrasound findings, administered the Bayley Scales of Infant Development-Second Edition. Children with an impairment (eg., blindness) that precluded testing with the Bayley Scales and those for whom >2 test items were omitted were classified using the Vineland Adaptive Behavior Scales Motor Skills Domain instead of the Psychomotor Development Index and the Adaptive Behavior Composite instead of the Mental Development Index.

RESULTS. Fully 26% of all of the children had delayed mental development (ie, Mental Development Index < 70), and 31% had delayed psychomotor development (ie, Psychomotor Development Index < 70). Ultrasound abnormalities were more strongly associated with low Psychomotor Development Index than with low Mental Development Index. Children without cranial ultrasound abnormality had the lowest probability (23% and 26%) of delayed mental or psychomotor development. Moderate/severe ventriculomegaly was associated with a more than fourfold increase in the risk of psychomotor delay and an almost threefold increase in the risk of mental delay. Echoluency was the next best predictor of delayed mental and psychomotor development. The probability of low scores varied with the number of zones involved and with the location of echoluency. At particularly high risk were

www.pediatrics.org/cgi/doi/10.1542/peds.2008-0594

doi:10.1542/peds.2008-0594

Key Words

prematurity, cognitive development, intraventricular hemorrhage, periventricular leukomalacia, neonatal follow-up, Bayley Scales of Infant Development

Abbreviations

ELGAN—Extremely Low Gestational Age Newborn
IVH—intraventricular hemorrhage
GMH—germinal matrix hemorrhage
BSID-II—Bayley Scales of Infant Development-Second Edition
MDI—Mental Development Index
PDI—Psychomotor Development Index
VABS—Vineland Adaptive Behavior Scales
ABC—Adaptive Behavior Composite
PVI—periventricular hemorrhagic infarction
PVL—periventricular leukomalacia
CI—confidence interval
RR—risk ratio

Accepted for publication May 13, 2008

Address correspondence to T. Michael O'Shea, MD, MPH, Wake Forest University Health Sciences, Department of Pediatrics, Medical Center Boulevard, Winston-Salem, NC 27157. E-mail: moshea@wfbmc.edu

PEDIATRICS (ISSN Numbers: Print, 0031-4005; Online, 1098-4275). Copyright © 2008 by the American Academy of Pediatrics

infants with bilateral cerebellar hemorrhage, co-occurring ventriculomegaly and echolucency bilateral echolucency, or echolucency located posteriorly.

CONCLUSIONS. Focal white matter damage, as characterized by echolucent/hypoechoic lesion, and diffuse damage, as suggested by late ventriculomegaly, are associated with delayed mental and psychomotor development. *Pediatrics* 2008;122:e662–e669

CRANIAL ULTRASONOGRAPHY IS widely used to identify neonates at increased risk for neurodevelopmental impairment.^{1–3} Attempts to summarize studies of the predictive value of cranial ultrasound abnormalities are made difficult by inconsistent approaches to classifying abnormalities.⁴ However, in low birth weight^{5–8} and preterm newborns,^{9–13} cranial ultrasound abnormalities indicative of white matter damage⁴ are the strongest predictors of cerebral palsy and developmental delay. The purpose of this study was to describe relationships between cranial ultrasound abnormalities and delayed development at 2 years of age in a large cohort of extremely premature infants. Elsewhere we report on relationships between ultrasound abnormalities and cerebral palsy.¹⁴

METHODS

The Extremely Low Gestational Age Newborns Study

The Extremely Low Gestational Age Newborns (ELGAN) study was designed to identify characteristics and exposures that increase the risk of structural and functional neurologic disorders in extremely low gestational age newborns. During the years 2002–2004, women delivering before 28 weeks' gestation at 1 of 14 participating institutions in 11 cities in 5 states were asked to enroll in the study. At each site, the study protocol was approved by an institutional review board.

Mothers were approached for consent before or shortly after delivery, depending on clinical circumstance and institutional preference. A total of 1249 mothers of 1506 infants consented. Approximately 260 women were missed or did not agree to participate.

Cranial Ultrasound Scans

Routine scans were performed by technicians at all of the hospitals using digitized high-frequency transducers (7.5 and 10.0 MHz). Ultrasound studies always included 6 standard paracoronal views and 5 parasagittal views through the anterior fontanel.¹⁵

Of 1506 infants enrolled, 1445 had ≥ 1 set of protocol ultrasound scans, and 895 had all 3 of the sets. Protocol 1 scans were obtained between the first and fourth day ($n = 1123$); protocol 2 scans, between the fifth and 14th day ($n = 1302$); and protocol 3 scans, between the 15th day and the 40th week postmenstrual age ($n = 1268$). In this article we refer to protocol 1 and 2 scans as "early" and protocol 3 scans as "late."

Previously we have described efforts taken in the ELGAN study to enhance the reliability of ultrasound

readings.¹⁶ Before patient enrollment, sonologists created a manual and data collection form and conducted reliability training exercises. During the study, each set of scans was first read by 1 study sonologist at the institution of the infant's birth. Digital images were then sent to a sonologist at another study institution for a second reading. When the 2 readers differed in their recognition of intraventricular hemorrhage (IVH), ventriculomegaly, echodensity, and echolucency, films were sent to a third (tie-breaking) reader who did not know what the initial readers reported.

Definitions of Ultrasound Abnormalities

Germinal matrix hemorrhage (GMH) was defined as blood localized to the subependymal region and IVH as blood within the ventricles. IVH excluded hemorrhage localized to the subependymal region. Ventriculomegaly, categorized as mild, moderate, and severe, was defined visually with a template on the data collection form.¹⁶ Our emphasis was on moderate/severe ventriculomegaly, which was diagnosed if a lateral ventricle was at least moderately enlarged in any of 4 sections (frontal horn, body, and occipital horn).

Developmental Assessment at 24 Months

Families were invited to bring their child for developmental assessment close to the time when he or she would attain 24 months' corrected age. This assessment included the Bayley Scales of Infant Development-Second Edition (BSID-II), a neurologic examination, and, when necessary, an interview of the parent using the Vineland Adaptive Behavior Scales.¹⁷ Fully 77% were assessed within the range of 23.5 to 27.9 months; of the others, approximately half were assessed before 23.5 months and approximately half after 27.9 months. In this article, the terms "delayed mental development" and "delayed psychomotor development" refer, respectively, to a Mental Developmental Index (MDI) of <70 and Psychomotor Developmental Index (PDI) of <70 .¹⁸

Bayley Scales of Infant Development-Second Edition.

Certified examiners administered and scored the BSID-II.¹⁸ All of the examiners had previous experience with the BSID-II and attended a 1-day workshop at which the published guidelines for test administration and videotaped examinations were viewed and discussed. Examiners were aware of infants' enrollment in the ELGAN study but were not informed of any specifics of the child's medical history. Before testing, examiners were told the child's corrected age; after testing they were told the birth date so that unadjusted BSID-II scores could be assigned.

When a child's impairment(s) precluded administration of the BSID-II or >2 items were omitted or judged to be "unscorable," the child was classified as not testable on that scale. Children considered nontestable with the BSID-II were assessed with the Vineland Adaptive Behavior Scales (VABS). Those with VABS Adaptive Behavior Composite (ABC) <70 were combined with infants with an MDI of <70 ; those with ABC ≥ 70 were

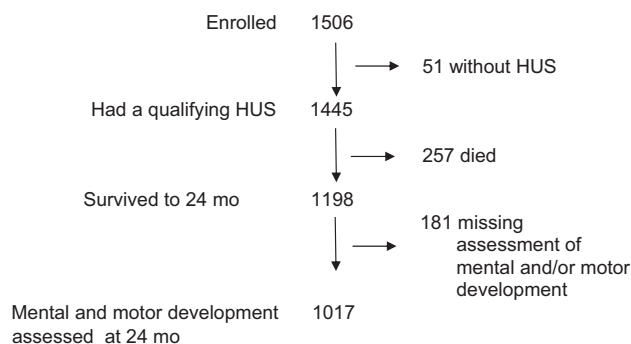


FIGURE 1 Description of the study sample. HUS indicates cranial ultrasound.

combined with infants whose MDI was ≥ 70 . Among infants nontestable with the BSID-II motor scale, those with a VABS motor skills domain score < 70 were combined with infants whose PDI was < 70 ; those with a score ≥ 70 were combined with infants with a PDI of ≥ 70 .

Data Analysis

For each ultrasound lesion, we computed the proportion of children who had an MDI or PDI of < 70 . To describe the strength of association between ultrasound lesions and developmental delay, we calculated risk ratios (RRs) and 95% confidence intervals (CIs) and adjusted for gestational age, antenatal glucocorticoid exposure, and medical care insurance at the time of the examination (private versus public), a surrogate for socioeconomic status.

RESULTS

Figure 1 depicts the study sample. Of the 257 deaths, 235 deaths occurred in the NICU. Comparing the 1017 infants who survived to 24 months' adjusted age and were assessed for mental and motor development with the 181 infants who survived but did not undergo a complete developmental assessment, the latter had mothers who were younger, less well educated, less likely to be married, less likely to support themselves via their own employment, and more likely to have Medicaid or other public insurance, but the 2 groups did not differ with regard to gender, plurality, gestational age, birth weight, birth weight z score, Score for Neonatal Acute Physiology II, or the frequency of ultrasound lesions.

Infants Not Testable With the BSID-II

The VABS ABC was obtained for 26 of 33 children who were nontestable with the BSID-II mental scale, and 23 had ABC < 70 . The VABS motor skills domain score was obtained for 32 of 38 children nontestable with the BSID-II motor scale, and 27 had a motor skills domain < 70 . Based on either the BSID-II or the VABS, 26% of study infants ($n = 269$) had delayed mental development, and 31% ($n = 314$) had delayed psychomotor development.

TABLE 1 Percentage of Children Who Had the Ultrasound Lesion Listed on the Left Who Had BSID-II Scores of < 70

Ultrasound Lesion	Percentage With MDI < 70	Percentage With PDI < 70	<i>n</i>
GMH	33	39	299
IVH	35	43	309
Ventriculomegaly	46	55	100
Echodense lesion	35	49	130
Echolucent lesion	45	61	71
IVH only	31	34	91
Ventriculomegaly only	42	33	12
Echodense lesion only	22	36	45
Echolucent lesion only	33	52	21
No ultrasound lesion	23	26	716
Diagnosis			
Early PVL	31	43	103
Cystic PVL	40	60	45
PVHI	44	59	54
<i>N</i>	269	314	1017

The numbers are row percentages with each lesion considered regardless of any other lesion the child might have had and then with each lesion when no others were present. GMH and IVH include infants with other lesions.

Overview

Among children whose scans showed IVH, only 32% had no other ultrasound abnormality (Table 1). Fully 42% had ventriculomegaly, 43% had a white matter echodensity, and 20% had a white matter echolucency. Thus, the findings presented here should be seen as conveying overlapping information. Among the 716 study children who had no ultrasound abnormality, 23% had delayed mental development, and 26% had delayed psychomotor development. Ultrasound abnormalities were more strongly associated with delayed psychomotor development than delayed mental development. The finding of ventriculomegaly and the diagnosis of periventricular hemorrhagic infarction (PVHI) were associated with a doubling of the risk of delayed mental development; other abnormalities were associated with more modest increases in risk. Ventriculomegaly, echolucency, and diagnoses of cystic periventricular leukomalacia (PVL) or PVHI were associated with the highest risks (57%–60%) of delayed psychomotor development. Depending on the presence of other ultrasound abnormalities, between 80% and 100% of children who had both ventriculomegaly and echolucency had delayed psychomotor development.

Hemorrhage

Unilateral GMH predicted delayed mental development as well as bilateral GMH, and better than unilateral IVH (Table 2). Generally, blood in the germinal matrix or any ventricle predicted delayed psychomotor development better than it predicted delayed mental development. Children who had bilateral cerebellar hemorrhages were at highest risk of developmental delays.

Early and Late Moderate/Severe Ventriculomegaly

Almost all of the children with ventriculomegaly had diffuse ventriculomegaly (Table 3). Consequently, enlargement of a particular area of the ventricle did not

TABLE 2 Percentage of Infants Whose Scan Had a Hemorrhage (Probable or Definite) in the Location Listed on the Left, Who Had BSID-II Scores of <70

Hemorrhage	Percentage With MDI < 70	Percentage With PDI < 70	n
Germinal matrix			
Unilateral	34	35	139
Bilateral	33	43	157
Lateral ventricle			
Unilateral	20	33	79
Bilateral	40	46	134
Third ventricle	46	54	68
Fourth ventricle	43	47	30
Cerebellar			
Unilateral	0	67	3
Bilateral	73	73	11
N	269	314	1017

Among children with no ultrasound lesion, 22% had an MDI of <70 and 24% had a PDI of <24%.

convey appreciably more predictive information about MDI or PDI scores than any other area. Except in the case of unilateral ventriculomegaly as a predictor of an MDI of <70, risks of developmental delays were higher among children with late, as compared with early, ventriculomegaly. However, rates of these delays were similar for children with bilateral, as compared with unilateral, ventriculomegaly.

Laterality of Echodense and Echolucent Lesions

Unilateral echodensity did as well as bilateral echodensity and unilateral echolucency in predicting developmental delays but not as well as bilateral echolucency (Table 4). Among infants with unilateral echodensity, those with right-sided echodensity more often had delayed mental development, whereas, among infants with unilateral echolucency, those with left-sided echolucency more often had delayed psychomotor development.

Extent of Echodensity and Echolucency Lesions

The risks of delayed mental or psychomotor developments increased as the numbers of zones with unilateral

TABLE 3 Percentage of Infants Whose Scan Had Ventriculomegaly (Moderate or Severe) Identified Either on the First or Second Study (Early Scan) or on the Third Study (Late Scan) Unilaterally or Bilaterally, Who Had BSID-II Scores of <70

Ventriculomegaly	Percentage With MDI < 70	Percentage With PDI < 70	n
Early			
Unilateral	40	50	10
Bilateral	38	41	32
N	267	311	1004
Late			
Unilateral	40	73	15
Bilateral	56	63	48
N	260	306	981

TABLE 4 Percentage of Infants With Echodensity or Echolucency Who Had BSID-II Scores of <70

Variable	Percentage With MDI < 70	Percentage With PDI < 70	n
Echodense lesion			
Unilateral	30	41	70
Right	39	39	36
Left	21	44	34
Bilateral	35	46	124
Echolucent lesion			
Unilateral	30	43	44
Right	28	28	18
Left	31	54	26
Bilateral	57	71	23
N	269	314	1017

echodensity increased; similarly, the risk of delayed mental development increased as the number of zones with bilateral echolucency increased (data not shown). No trends were apparent for the relationship between the number of zones of bilateral echodensity or unilateral echolucency and delayed development.

Location of Echodensity and Echolucency Lesions

Risks of delayed mental and psychomotor development were higher when echolucency was found in posterior zones as compared with anterior zones (Table 5 and Fig 2). The 16 children who had an echolucency in the parietal-occipital white matter seen high on the "over-the-top" view were at very high risk of delayed psychomotor (88%) and mental development (75%). Infants with echolucency in the 3 zones located closest to the motor cortex did not have a higher rate of delayed psychomotor development than infants with echolucency confined to other zones. An echolucency in the paraventricular white matter seen on the "trigone" view

TABLE 5 Percentage of Infants Whose Scan Had an Echodensity or Echolucency in Any of the Anterior or Posterior Zones Who Had BSID-II Scores of <70

Location	Echodensity			Echolucency		
	Percentage With MDI < 70	Percentage With PDI < 70	n	Percentage With MDI < 70	Percentage With PDI < 70	n
Unilateral						
Anterior	38	46	48	24	42	33
Posterior	19	35	31	55	55	11
Bilateral						
Anterior	35	48	89	56	69	16
Posterior	37	45	78	67	83	12
Early						
Anterior	36	48	88	15	38	13
Posterior	31	38	72	67	67	3
Late						
Anterior	38	49	47	41	54	39
Posterior	22	39	18	71	82	17

Anterior zones are labeled A, B, C, F, and J in Fig 2, and posterior zones are labeled G, K, N, P, and R in Fig 2.

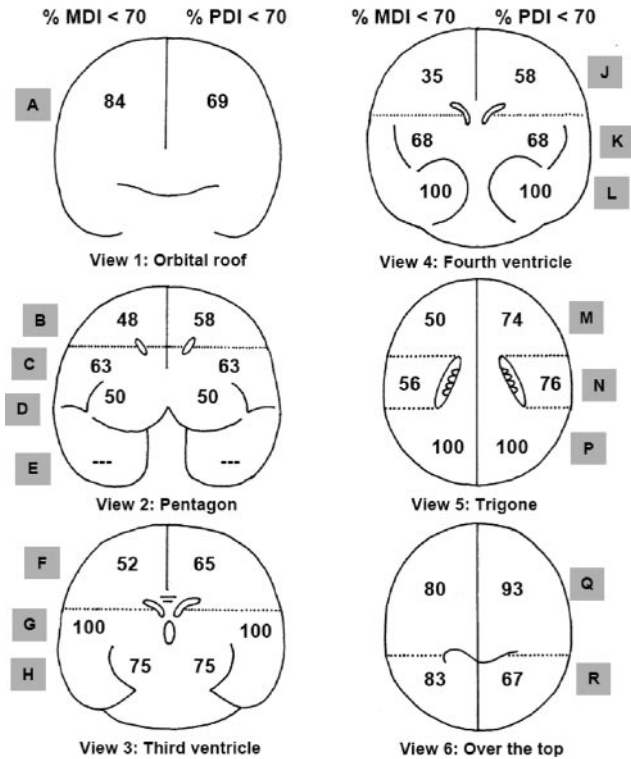
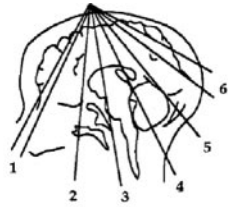


FIGURE 2 Percentage of children whose scan had an echolucency in a particular location and who had an MDI of <70 (black numbers on the left side of the brain) or a PDI of <70 (black numbers on the right side of the brain) on the BSID-II. The letters inside the shaded boxes indicate the zones as listed in Table 5.

also conveyed high risks of delayed psychomotor development.

RRs and Test Characteristics

The highest RR for delayed mental development was associated with ventriculomegaly (RR: 2.70 [95% CI: 1.70–4.10]), followed by PVHI (RR: 1.90 [95% CI: 1.05–2.40]). Ventriculomegaly had the highest RR for delayed psychomotor development (RR: 4.40 [95% CI: 2.90–6.90]), followed by PVHI (RR: 3.90 [95% CI: 2.20–7.10]), echolucency (RR: 3.70 [95% CI: 2.30–6.10]), and cystic PVL (RR: 3.60 [95% CI: 2.20–7.10]). The predictive value of an ultrasound with ventriculomegaly or echolucency was 45% to 61%, which corresponds with likelihood ratios of 2.0 to 2.5. Because the sensitivity of these findings was low, the negative likelihood ratio for the absence of ventriculomegaly and echolucency is only slightly <1 (Tables 6 and 7).

DISCUSSION

We evaluated the relationship between neonatal cranial ultrasound findings and standardized developmental as-

TABLE 6 RRs and 95% CIs for a Bayley Scale Scores of <70, Calculated Separately for MDI and PDI Associated With Each Ultrasound Lesion or Diagnosis

Variable	RR (95% CI) for MDI < 70	RR (95% CI) for PDI < 70
Ultrasound lesion		
IVH	1.70 (1.20–2.50)	2.10 (1.50–2.90)
Ventriculomegaly	2.90 (1.80–4.60)	3.60 (2.30–5.60)
Echodensity	1.70 (1.10–2.60)	2.80 (1.90–4.20)
Echolucency	2.70 (1.60–4.50)	4.60 (2.70–7.80)
Diagnosis		
Early PVL	1.30 (0.80–2.10)	2.10 (1.40–3.20)
Cystic PVL	1.90 (0.98–3.50)	4.30 (2.30–8.10)
PVHI	2.20 (1.20–4.00)	4.00 (2.20–7.00)

The referent group for each ultrasound lesion or diagnosis consists of children who had none of the lesions or diagnoses, whereas children with lesions and/or diagnoses may have other lesions or diagnoses. The models are adjusted for gestational age (23–24, 25–26, or 27 weeks), receipt of a complete course of antenatal corticosteroid, cesarean delivery, and Medicaid insurance at 2 years' corrected age.

essments in extremely low gestational age neonates. As have others, we found that cranial ultrasound abnormalities are more strongly associated with delayed development of skills assessed with the PDI than those assessed with the MDI.^{19–21} and that ventriculomegaly and echolucency are the ultrasound findings associated most strongly with delayed infant development.^{9,22} Among ultrasound diagnoses, cystic PVL and PVHI are associated most strongly with developmental delay,^{5,12,13} although bilateral cerebellar hemorrhage, found in 1% of our cohort, may be comparably predictive of adverse outcome. The lower predictive value of echodensity is to be expected, because the reliability of cranial ultrasound interpretations used in our study was lower for echodensity ($\kappa = 0.3$), as compared with IVH, ventriculomegaly, and echolucency ($\kappa > 0.6$).¹⁶ The frequency of an MDI of <70 described here (26%) is similar to that observed in a cohort born at 23 to 27 weeks,²³ and the rate that we observed among infants without ultrasound abnormalities (23%) is similar to that of a cohort with a birth weight of 401 to 1000 g.²⁴

We found evidence that the risk of developmental delay varies with laterality, location, and extent of white matter abnormalities. For example, bilateral echolucency was associated more strongly with delayed development than unilateral echolucency.^{3,25,26} Unexpected are our findings that unilateral ventriculomegaly is as

TABLE 7 Measures of the Ability of Head Ultrasound Abnormalities Evident Before Discharge From the NICU to Predict an MDI or PDI > 2 SDs Below the Expected Mean at 24 Months' Corrected Age

Ultrasound Lesion, Bayley Scale < 70	Ventriculomegaly		Echolucent Lesion	
	MDI	PDI	MDI	PDI
Predictive value positive	45	55	45	61
Predictive value negative	76	72	75	71
Sensitivity	17	17	12	14
Specificity	93	94	95	96

strongly associated with low PDI as is bilateral ventriculomegaly and that unilateral echodensity is as strongly associated with low BSID-II scores as is bilateral echodensity.

Others have found that ultrasound abnormalities are associated with a twofold to fourfold increase in the risk of low BSID-II scores⁵ and mental retardation.²⁷ These include the findings of ventriculomegaly and echolucency, which most often are seen after the initial scan^{9,10,28,29}; the diagnosis of PVHI, which often is present on scans performed in the first weeks of life^{30–32}; and cystic PVL, which typically is not present until several weeks after birth.^{9,28,29}

In the only study we found that assessed whether the hemispheric side of white matter lesions influences developmental outcome, intelligence quotients were higher and visual motor integration was better at 8 years of age among children born preterm who had right-sided cerebral lesions as compared with those with left-sided lesions.²⁵ In the current study, infants with right-sided echolucency had better scores for PDI, but those with right-sided echodensity had worse scores for MDI. Most likely these right-left differences are because of random variation.

In this study, unilateral ventriculomegaly seen on early ultrasound (ie, the first 14 days) was more predictive of low BSID-II than was bilateral ventriculomegaly. In contrast, fetuses with unilateral³³ or bilateral ventriculomegaly³⁴ typically have normal developmental outcome.

The stronger association between cranial ultrasound abnormalities and a PDI of <70, as compared with an MDI of <70, might relate, in part, to the greater contribution of periventricular brain structures, such as corticospinal tracts, to functions assessed with the PDI, such as perceptual-motor integration, sensory integration, and quality of movement.¹⁸ On the other hand, substantial white matter is located in associative areas, which influence cognitive abilities, such as those assessed with the MDI (eg, memory, problem-solving skills, and language development). In addition, children who have early imaging evidence of periventricular white matter damage also have reduced cortical volume.³⁵ This has been attributed to damage to myelin-producing cells³⁶ and neurons, which migrate to the cortex through injured white matter.³⁷ Such damage might be more diffuse and widespread with ventriculomegaly and more focal with echolucency.

The importance of the cerebellum in cognitive development is supported by studies correlating cerebellar size and scores on cognitive testing³⁸ and studies of developmental outcome after cerebellar hemorrhage.^{39,40} After the advent of neonatal intensive care, cerebellar hemorrhage was described in autopsy studies of preterm infants.⁴¹ After ultrasound imaging improved, this lesion could be identified in surviving infants.^{39,40} As have others,⁴² we found that ~3 of every 4 infants with cerebellar hemorrhage had delayed psychomotor development and that more than half had delayed mental development.

If ultrasound detected all, or most, white matter damage, we would expect the risk of low BSID-II scores to be

higher with bilateral, as compared with unilateral, ventriculomegaly and with bilateral, as compared with unilateral, echodensity; but we observed neither. In addition, the risk of low BSID-II scores did not increase in a graded fashion with an increasing extent of unilateral echolucency. Finally, as reported by others,²⁴ we found that approximately one quarter of extremely premature infants with normal ultrasounds have BSID-II scores <70.

The most parsimonious explanation for these findings is that ultrasound detects only a fraction of the total white matter damage. Support for this hypothesis, referred to as the “tip-of-the-iceberg” hypothesis,³⁶ comes from studies correlating ultrasound findings with either MRI^{43,44} or postmortem examination.⁴⁵ In addition, ~50% of infants who develop cerebral palsy have ultrasound abnormality.^{7,46,47} A likely explanation for our finding that echodensity and echolucency were found predominantly in zones located superior to the lateral ventricles and were infrequently seen in zones closest to the temporal lobes and zones closest to the occipital lobes is better visualization of the superior aspects of the brain when using an ultrasound through the anterior fontanelle.

Perhaps the main limitation of this study was our dependence on ultrasound to identify white matter damage. Early MRI does a much better job, especially of detecting diffuse white matter damage.^{48–50} Thus, the study might have misclassified some scans as not showing white matter damage, when, indeed, an MRI would have identified white matter damage.

Strengths of this study include the large sample⁵¹ based on gestational age rather than birth weight,⁵² efforts to minimize interobserver disagreements about ultrasound findings,¹⁶ efforts to standardize the administration of the BSID-II and minimize examiners’ knowledge of the infants’ clinical histories, and the high proportion of infants with ultrasounds obtained after the first month of life, when white matter damage may be seen for the first time.⁹ Finally, to classify study participants who were not testable with the BSID, we used proxy measures of developmental status in an effort to decrease bias (ie, “missing clinical data bias”⁵³).

The most important implication of our study is that clinicians can use ultrasound markers of white matter damage (ventriculomegaly, echodensity, and echolucency^{4,36,45,54}) as predictors of developmental impairment.^{13,25,27,55} Children with these markers can be targeted for early intervention to improve developmental outcome.^{56,57} This use of ultrasound is part of the basis for the Practice Parameter for Neuroimaging of the Neonate in 2002,⁴¹ which recommends cranial ultrasound screening for infants born before 30 weeks’ gestation, at 7 to 14 days, and again at 36 to 40 weeks. In a study of very preterm infants, the sensitivity of major ultrasound abnormalities (ie, Papile grade III hemorrhage, echodensity, echolucency, and basal ganglia lesions) for prediction of cerebral palsy was 95% and the specificity was 99%.⁹ The sensitivity and specificity are lower for the prediction of other developmental impairments, particularly nonmotor impairments. In a multicenter study of

2103 infants, the sensitivity, specificity, and likelihood ratio positive for cystic PVL for identifying infants with a PDI of <70 were, respectively, 0.30, 0.80, and 6.00,⁵⁸ as compared with the values reported here for echolucency (0.14, 0.96, and 3.50). Similar likelihood ratios for the prediction of a PDI of <70 were reported from studies of an index of chronic physiologic instability⁵⁹ and the Nursery Neurobiological Risk Score.⁶⁰ Thus, when the clinical goal is prediction of low scores on the BSID-II, other clinical information may be complementary to,⁵⁹ or even more valuable than,⁵⁸ cranial ultrasonography. Alternative methods, such as MRI^{48,49} or more frequent scanning with ultrasound,⁹ might improve the predictive value of neuroimaging. Nonetheless, the information provided here can be used cautiously to counsel parents and plan for developmental services for infants at high risk.

ACKNOWLEDGMENTS

Financial support for this research was provided by National Institute of Neurological Disorders and Stroke grant NS 40069.

We thank Rebecca Helms, PhD (East Carolina University) and Lynn Whitley, PhD (East Carolina University) for completing some of the developmental assessments on which this article was based.

REFERENCES

- Ment LR, Bada HS, Barnes P, et al. Practice parameter: neuroimaging of the neonate-report of the Quality Standards Subcommittee of the American Academy of Neurology and the Practice Committee of the Child Neurology Society. *Neurology*. 2002;58(12):1726–1738
- Paneth N, Rudelli R, Kazam E, Monte W. Prognosis. In: Paneth N, Rudelli R, Kazam E, Monte W, eds. *Brain Damage in the Preterm Infant*. London, United Kingdom: Cambridge University Press; 1994:171–185
- Holling EE, Leviton A. Characteristics of cranial ultrasound white-matter echolucencies that predict disability: a review. *Dev Med Child Neurol*. 1999;41(2):136–139
- Paneth N. Classifying brain damage in preterm infants. *J Pediatr*. 1999;134(5):527–529
- Vohr BR, Wright LL, Dusick AM, et al. Neurodevelopmental and functional outcomes of extremely low birth weight infants in the National Institute of Child Health and Human Development Neonatal Research Network, 1993–1994. *Pediatrics*. 2000;105(6):1216–1226
- Aziz K, Vickar DB, Sauve RS, Etches PC, Pain KS, Robertson CM. Province-based study of neurologic disability of children weighing 500 through 1249 grams at birth in relation to neonatal cerebral ultrasound findings. *Pediatrics*. 1995;95(6):837–844
- Pinto-Martin JA, Riolo S, Cnaan A, Holzman C, Susser MW, Paneth N. Cranial ultrasound prediction of disabling and non-disabling cerebral palsy at age two in a low birth weight population [published correction appears in *Pediatrics*. 2001;108(2):238]. *Pediatrics*. 1995;95(2):249–254
- Pinto-Martin JA, Whitaker AH, Feldman JF, Van Rossem R, Paneth N. Relation of cranial ultrasound abnormalities in low-birthweight infants to motor or cognitive performance at ages 2, 6, and 9 years. *Dev Med Child Neurol*. 1999;41(12):826–833
- De Vries LS, Van Haastert ILC, Rademaker KJ, Koopman C, Groenedaal F. Ultrasound abnormalities preceding cerebral palsy in high-risk preterm infants. *J Pediatr*. 2004;144(6):815–820
- Stewart AL, Reynolds EO, Hope PL, et al. Probability of neurodevelopmental disorders estimated from ultrasound appearance of brains of very preterm infants. *Dev Med Child Neurol*. 1987;29(1):3–11
- Roth SD, Baudin J, Pezzani-Goldsmith M, Townsend J, Reynolds EOR, Stewart AL. Relation between neurodevelopmental status of very preterm infants at one and eight years. *Dev Med Child Neurol*. 1994;36(12):1049–1062
- Fily A, Pierrat V, Delporte V, Breart G, Truffert P. Factors associated with neurodevelopmental outcome at 2 years after very preterm birth: the population-based Nord-Pas-de-Calais EPIPAGE cohort. *Pediatrics*. 2006;117(2):357–366
- Wood NS, Costeloe K, Gibson AT, Hennessy EM, Marlow N, Wilkinson AR. The EPICure study: associations and antecedents of neurological and developmental disability at 30 months of age following extremely preterm birth. *Arch Dis Child Fetal Neonatal Ed*. 2005;90(2):F134–F140
- Kuban K, Allred E, O’Shea TM, et al. Cranial ultrasound lesions in the NICU predict cerebral palsy at age 2 years in children who were born at extremely low gestational age. *J Child Neurol*. 2008; In press
- Teele R, Share J. *Ultrasonography of Infants and Children*. Philadelphia, PA: WB Saunders; 1991
- Kuban K, Adler I, Allred E, et al. Observer variability assessing US scans of the preterm brain: the ELGAN study. *Pediatr Radiol*. 2007;37(12):1201–1208
- Sparrow SS, Balla DA, Cicchetti DV. *Vineland Adaptive Behavioral Scales*. Circle Pines, MN: American Guidance Service; 1984
- Bayley N. *Bayley Scales of Infant Development*. 2nd ed. San Antonio, TX: Psychological Corporation; 1993
- Graziani LJ, Pasto M, Stanley C, et al. Cranial ultrasound and clinical studies in preterm infants. *J Pediatr*. 1985;106(2):269–276
- Kitchen WH, Ford GW, Murton LJ, et al. Mortality and two year outcome of infants of birthweight 500–1500 g: relationship with neonatal cerebral ultrasound data. *Aust Paediatr J*. 1985;21(4):253–259
- Vohr BR, Wright LL, Poole K, McDonald SA; NICHD Neonatal Research Network Follow-up Study. Neurodevelopmental outcomes of extremely low birth weight infants <32 weeks’ gestation between 1993 and 1998. *Pediatrics*. 2005;116(3):635–643
- Whitaker A, Johnson J, Sebris S, et al. Neonatal cranial ultrasound abnormalities-association with developmental delay at age one in low-birth-weight infants. *J Dev Behav Pediatr*. 1990;11(5):253–260
- Doyle LW; Victorian Infant Collaborative Study Group. Neonatal intensive care at borderline viability-is it worth it? *Early Hum Deve*. 2004;80(2):103–113
- Laptook AR, O’Shea TM, Shankaran S, Bhaskar B; NICHD Neonatal Network. Adverse neurodevelopmental outcomes among extremely low birth weight infants with a normal head ultrasound: prevalence and antecedents. *Pediatrics*. 2005;115(3):673–680
- Vollmer B, Roth S, Riley K, et al. Long-term neurodevelopmental outcome of preterm children with unilateral cerebral lesions diagnosed by neonatal ultrasound. *Early Hum Dev* 2006;82(10):655–661
- Cooke RWI. Early and late cranial ultrasonographic appearances and outcome in very low birthweight infants. *Arch Dis Child*. 1987;62(9):931–937
- Whitaker AH, Feldman JF, Van Rossem R, et al. Neonatal cranial ultrasound abnormalities in low birth weight infants: relation to cognitive outcomes at six years of age. *Pediatrics*. 1996;98(4 pt 1):719–729

28. Fawer CL, Calame A, Perentes E, Andereg A. Periventricular leukomalacia: a correlation study between real-time ultrasound and autopsy findings: periventricular leukomalacia in the neonate. *Neuroradiology*. 1985;27(4):292–300
29. Costeloe K, Hennessy E, Gibson AT, Marlow N, Wilkinson AR. The EPICure study: outcomes to discharge from hospital for infants born at the threshold of viability. *Pediatrics*. 2000;106(4):659–671
30. Guzzetta F, Schackelford GD, Volpe S, Perlman JM, Volpe JJ. Periventricular intraparenchymal echodensities in the premature newborn: critical determinant of neurologic outcome. *Pediatrics*. 1986;78(6):995–1006
31. Nwaesei CG, Pape KE, Martin DJ, Becker LE, Fitz CR. Periventricular infarction diagnosed by ultrasound: a postmortem correlation. *J Pediatr*. 1984;105(1):106–110
32. Bassan H, Feldman HA, Limperopoulos C et al. Periventricular hemorrhagic infarction: Risk factors and neonatal outcome. *Pediatr Neurol*. 2006;35(2):85–92
33. Durfee SM, Kim FM, Benson CB. Postnatal outcome of fetuses with the prenatal diagnosis of asymmetric hydrocephalus. *J Ultrasound Med*. 2001;20(3):263–268
34. Bloom SL, Bloom DD, Dellanebbia C, Martin LB, Lucas MJ, Twickler DM. The developmental outcome of children with antenatal mild isolated ventriculomegaly. *Obstet Gynecol*. 1997;90(1):93–97
35. Vasileiadis GT, Gelman N, Williams LA, et al. Uncomplicated intraventricular hemorrhage reduces the cortical gray matter volume in preterm neonates. *Pediatr Res*. 2003;53(4):511A
36. Leviton A, Gilles F. Ventriculomegaly, delayed myelination, white matter hypoplasia, and “periventricular” leukomalacia: how are they related? *Pediatr Neurol*. 1996;15(2):127–136
37. Leviton A, Gressens P. Neuronal damage accompanies perinatal white-matter damage. *Trends Neurosci*. 2007;30(9):473–478
38. Allin M, Matsumoto H, Santhouse AM, et al. Cognitive and motor function and the size of the cerebellum in adolescents born very pre-term. *Brain*. 2001;124(pt 1):60–66
39. Johnsen SD, Tarby TJ, Lewis KS, Bird R, Prenger E. Cerebellar infarction: an unrecognized complication of very low birth-weight. *J Child Neurol*. 2002;17(5):320–324
40. Bodensteiner JB, Johnsen SD. Cerebellar injury in the extremely premature infant: newly recognized but relatively common outcome. *J Child Neurol*. 2005;20(2):139–142
41. Paneth N, Rudelli R, Kazam E, Monte W. Associated pathologic lesions: cerebellar hemorrhage, pontosubicular necrosis, basal ganglia necrosis. In: Paneth N, Rudelli R, Kazam E, Monte W, eds. *Brain Damage in the Preterm Infant*. London, United Kingdom: Cambridge University Press; 1994:163–170
42. Limperopoulos C, Bassan H, Gauvreau K, et al. Does cerebellar injury in premature infants contribute to the high prevalence of long-term cognitive, learning, and behavioral disability in survivors? *Pediatrics*. 2007;120(3):584–593
43. Inder TE, Anderson NJ, Spencer C, Wells S, Volpe JJ. White matter injury in the premature infant: A comparison between serial cranial sonographic and MR findings at term. *Am J Neuroradiol*. 2003;24(5):805–809
44. Maalouf EF, Duggan PJ, Counsell SJ, et al. Comparison of findings on cranial ultrasound and magnetic resonance imaging in preterm infants. *Pediatrics*. 2001;107(4):719–727
45. Paneth N, Rudelli R, Monte W, et al. White matter necrosis in very low birth weight infants: neuropathologic and ultrasonographic findings in infants surviving six days or longer. *J Pediatr*. 1990;116(6):975–984
46. O’Shea TM, Klinepeter KL, Dillard RG. Prenatal events and the risk of cerebral palsy in very low birth weight infants. *Am J Epidemiol*. 1998;147(4):362–369
47. Wheeler M, Rennie JM. Perinatal infection is an important risk factor for cerebral palsy in very-low-birthweight infants. *Dev Med Child Neurol*. 2000;42(6):364–367
48. Miller SP, Cozzio CC, Goldstein RB, et al. Comparing the diagnosis of white matter injury in premature newborns with serial MR imaging and transfontanel ultrasonography findings. *Am J Neuroradiol*. 2003;24(8):1661–1669
49. Mirmiran M, Barnes PD, Keller K, et al. Neonatal brain magnetic resonance imaging before discharge is better than serial cranial ultrasound in predicting cerebral palsy in very low birth weight preterm infants. *Pediatrics*. 2004;114(4):992–998
50. Woodward LJ, Anderson PJ, Austin NC, Howard K, Inder TE. Neonatal MRI to predict neurodevelopmental outcomes in preterm infants. *N Engl J Med*. 2006;355(7):685–694
51. Kiely JL, Paneth N. Follow-up studies of low-birthweight infants: suggestions for design, analysis and reporting. *Dev Med Child Neurol*. 1981;23(1):96–100
52. Arnold CC, Kramer MS, Hobbs CA, McLean FH, Usher RH. Very low birth weight: a problematic cohort for epidemiologic studies of very small or immature neonates. *Am J Epidemiol*. 1991;134(6):604–613
53. Sackett DL. Bias in analytic research. *J Chron Dis*. 1979;32(1–2):51–63
54. Kuban K, Sanocka U, Leviton A, et al. White matter disorders of prematurity: association with intraventricular hemorrhage and ventriculomegaly. *J Pediatr*. 1999;134(539):546
55. Ment LR, Vohr B, Allan W, et al. The etiology and outcome of cerebral ventriculomegaly at term in very low birth weight preterm infants. *Pediatrics*. 1999;104(2 pt 1):243–248
56. Als H, Duffy FH, McAnulty GB, et al. Early experience alters brain function and structure. *Pediatrics*. 2004;113(4):846–857
57. Spittle AJ, Orton J, Doyle LW, Boyd R. Early developmental intervention programs post hospital discharge to prevent motor and cognitive impairments in preterm infants. *Cochrane Database Syst Rev*. 2007;(2):CD005495
58. Broitman E, Namasivayam A, Higgins RD, et al. Clinical data predict neurodevelopmental outcome better than head ultrasound in extremely low birth weight infants. *J Pediatr*. 2007;151(5):500–505
59. Mattia FR, deRegnier RA. Chronic physiologic instability is associated with neurodevelopmental morbidity at one and two years in extremely premature infants. *Pediatrics*. 1998;102(3). Available at: www.pediatrics.org/cgi/content/full/102/3/e35
60. Brazy JE, Eckerman CO, Oehler JM, Goldstein RF, O’Rand AM. Nursery Neurobiologic Risk Score: important factor in predicting outcome in very low birth weight infants. *J Pediatr*. 1991;118(5):783–792

Neonatal Cranial Ultrasound Lesions and Developmental Delays at 2 Years of Age Among Extremely Low Gestational Age Children

T. Michael O'Shea, Karl C. K. Kuban, Elizabeth N. Allred, Nigel Paneth, Marcello Pagano, Olaf Dammann, Lisa Bostic, Kara Brooklier, Samantha Butler, Donald J. Goldstein, Gail Hounshell, Cecelia Keller, Susan McQuiston, Alice Miller, Steve Pasternak, Susan Plesha-Troyke, Joan Price, Elaine Romano, Katherine M. Solomon, Amanda Jacobson, Sjirk Westra and Alan Leviton

Pediatrics 2008;122:e662

DOI: 10.1542/peds.2008-0594

Updated Information & Services	including high resolution figures, can be found at: http://pediatrics.aappublications.org/content/122/3/e662.full.html
References	This article cites 52 articles, 25 of which can be accessed free at: http://pediatrics.aappublications.org/content/122/3/e662.full.html#ref-list-1
Citations	This article has been cited by 10 HighWire-hosted articles: http://pediatrics.aappublications.org/content/122/3/e662.full.html#related-urls
Subspecialty Collections	This article, along with others on similar topics, appears in the following collection(s): Premature & Newborn http://pediatrics.aappublications.org/cgi/collection/premature_and_newborn
Permissions & Licensing	Information about reproducing this article in parts (figures, tables) or in its entirety can be found online at: http://pediatrics.aappublications.org/site/misc/Permissions.xhtml
Reprints	Information about ordering reprints can be found online: http://pediatrics.aappublications.org/site/misc/reprints.xhtml

PEDIATRICS is the official journal of the American Academy of Pediatrics. A monthly publication, it has been published continuously since 1948. PEDIATRICS is owned, published, and trademarked by the American Academy of Pediatrics, 141 Northwest Point Boulevard, Elk Grove Village, Illinois, 60007. Copyright © 2008 by the American Academy of Pediatrics. All rights reserved. Print ISSN: 0031-4005. Online ISSN: 1098-4275.

American Academy of Pediatrics

DEDICATED TO THE HEALTH OF ALL CHILDREN™

