Provided for non-commercial research and education use.
Not for reproduction, distribution or commercial use.



This article appeared in a journal published by Elsevier. The attached copy is furnished to the author for internal non-commercial research and education use, including for instruction at the authors institution and sharing with colleagues.

Other uses, including reproduction and distribution, or selling or licensing copies, or posting to personal, institutional or third party websites are prohibited.

In most cases authors are permitted to post their version of the article (e.g. in Word or Tex form) to their personal website or institutional repository. Authors requiring further information regarding Elsevier's archiving and manuscript policies are encouraged to visit:

http://www.elsevier.com/copyright

Author's personal copy

Neuroscience 162 (2009) 836–851

REVIEW

CURRENT ADVANCES IN LESION-SYMPTOM MAPPING OF THE HUMAN CEREBELLUM

D. TIMMANN,[a]* J. KONCZAK,[b] W. ILG,[c] O. DONCHIN,[d] J. HERMSDÖRFER,[e] E. R. GIZEWSKI[f] AND B. SCHOCH[g]

[a]*Department of Neurology, University of Duisburg-Essen, Hufelandstraße 55, 45138 Essen, Germany*

[b]*School of Kinesiology, University of Minnesota, 400 Cooke Hall, 1900 University Ave, SE, Minneapolis, MN 55455, USA*

[c]*Hertie Institute for Clinical Brain Research, University of Tübingen, Frondsbergstrasse 23, 72076 Tübingen, Germany*

[d]*Department of Biomedical Engineering, Ben Gurion University of the Negev, Be'er Sheva 84105, Israel*

[e]*Clinical Neuropsychology Research Group, Hospital Munich-Bogenhausen, Dachauer Strasse 164, 80992 Munich, Germany*

[f]*Department of Neuroradiology, University of Duisburg-Essen, Germany*

[g]*Department of Neurosurgery, University of Duisburg-Essen, Germany*

Abstract—While high-resolution structural magnetic resonance imaging (MRI) combined with newer analysis methods has become a powerful tool in human cerebral lesion studies, comparatively few studies have used these advanced imaging techniques to study lesions of the human cerebellum and their associated symptoms. This review will summarize the methodology of MRI-based lesion-symptom mapping of the human cerebellum and discuss its potential for gaining insights into cerebellar function. The investigation of patients with defined focal lesions yields the greatest potential for obtaining meaningful correlations between lesion site and behavioral deficits. In smaller groups of patients overlay plots and subtraction analysis are good options. If larger groups of patients are available, different statistical techniques have been introduced to compare behavior and lesion site on a voxel-by-voxel basis. Although localization in degenerative cerebellar disorders is less accurate because of the diffuse nature of the disease, certain information about the supposed function of larger subdivisions of the cerebellum can be gained. Examples are given which show that lesion-symptom mapping allows to investigate the function of the intermediate zone and cerebellar nuclei. We conclude that meaningful correlations between lesion site and behavioral data can be obtained in patients with degenerative as well as focal cerebellar disorders. **© 2009 IBRO. Published by Elsevier Ltd. All rights reserved.**

Key words: volumetry, voxel-based, intermediate zone, cerebellar nuclei, cerebellar stroke, functional compartmentalization.

Contents

Human cerebellar lesion conditions 837
Cerebellar stroke 837
Cerebellar tumors 839
Acute versus chronic focal lesions 840
Cerebellar (cortical) degeneration 840
Clinical ataxia rating scales 841
Lesion symptom mapping 842
Focal cerebellar lesions 842
Comparing lesion site in two groups of patients 842
Pooling brain images across predefined anatomical regions 842
Pooling brain images based on behavioral cutoffs 843
Subtraction analysis 843
Voxel-based lesion symptom mapping (VLSM) 845
Student's *t*-tests 845
Cerebellar (cortical) degeneration 845
Conventional cerebellar volumetry 846
Clinical ataxia scores 846
Adaptation to kinematic and dynamic errors 848
Voxel-based morphometry (VBM) 848
Conclusions 848
Acknowledgments 848
References 849

A traditional approach to elucidate the function of the human brain, and the cerebellum in particular, is to study impairment in human subjects with brain lesions. However, the approach suffers from a number of limitations (Shallice, 1988). The cerebellum is part of a more extended brain circuitry. Thus, a specific behavioral deficit following a localized cerebellar lesion may result from functional disruption anywhere within that circuitry. Furthermore, in patients with chronic lesions, plasticity within the cerebellum and the connected areas may lead to changes in their function as the brain attempts to recover. In patients with

*Corresponding author. Tel: +49-201-723-3816; fax: +49-201-723-5901. E-mail address: dagmar.timmann-braun@uni-duisburg-essen.de (D. Timmann).

Abbreviations: ADCA, autosomal dominant cerebellar ataxia; AICA, anterior inferior cerebellar artery; AVM, arteriovenous malformation; CT, computed tomography; DTI, diffusion tensor imaging; DWI, diffusion weighted imaging; EA2, episodic ataxia type 2; FF, force field perturbation; HVI, cerebellar hemispheral lobule VI according to Larsell; IB, impaired dynamic balance during gait; ICARS, International Cooperative Ataxia Rating Scale; IL, impaired leg placement; IPICA, lateral posterior inferior cerebellar artery branch; MNI, Montreal Neurological Institute; mPICA, medial posterior inferior cerebellar artery branch; MPRAGE, magnetization-prepared rapid-acquired gradient echo sequence; MRI, magnetic resonance imaging; MSA-C, multiple system atrophy, cerebellar type; mSCA, medial superior cerebellar artery branch; NIB, unimpaired dynamic balance during gait; NIL, unimpaired leg placement; PICA, posterior inferior cerebellar artery; ROI, region of interest; SAOA, sporadic adult onset ataxia; SARA, Scale for the Assessment and Rating of Ataxia; SCA, superior cerebellar artery; SCA(number), spinocerebellar ataxias type (number); SPM, statistical parametric mapping; SWI, susceptibility weighted imaging; TICV, total intracranial volume; VBM, voxel-based morphometry; VLSM, voxel-based lesion symptom mapping; VM, visuomotor rotation; WHO, World Health Organization; 3-D, three-dimensional.

0306-4522/09 $ - see front matter © 2009 IBRO. Published by Elsevier Ltd. All rights reserved.
doi:10.1016/j.neuroscience.2009.01.040

Author's personal copy

acute focal lesions, changes due to neural plasticity are not a problem. However, a temporary dysfunction in connected brain areas after abrupt changes in input is a serious problem in this patient group.

Although function of the cerebellum cannot be inferred from lesion data alone, it is still of major scientific and clinical interest if lesions of a given cerebellar area lead to specific behavioral deficits. The introduction of high-resolution structural brain imaging and new analysis methods has led to significant improvement in our ability to draw such conclusions (Rorden and Karnath, 2004). This review highlights these implications for human cerebellar lesion studies.

Despite the good quality of new generation computed tomography (CT), magnetic resonance imaging (MRI) is the method of choice for visualization of structures within the posterior fossa. In patients with cerebellar degeneration, volumetric MRI measures can be applied to quantify the degree of atrophy of the whole cerebellum and its major subdivisions (Makris et al., 2005; Brandauer et al., 2008). In patients with focal cerebellar lesions it is possible to define affected cerebellar lobules (Schmahmann et al., 2000; Gerwig et al., 2003, 2005). Furthermore, the cerebellar nuclei can be visualized with increasing precision, and it is now possible to determine which parts of the nuclei are affected in each patient (Dimitrova et al., 2002; Deoni and Catani, 2007).

Correlation of cerebellar lesion and behavioral data has greatest spatial precision in patients with focal lesions. In smaller groups of subjects, lesion overlay plots and subtraction analyses are useful approaches. These techniques allow comparison of lesion site between two groups of patients with and without impairment in a given task. Likewise, patients can be divided into a group with and a group without lesion in a specific area, and then behavior can be compared between the two groups. If larger groups of patients with focal lesions are available, innovative statistical techniques have been introduced to compare behavior and lesion site on a voxel-by-voxel basis (Bates et al., 2003; Rorden and Karnath, 2004; Rorden et al., 2007).

In patients with degenerative cerebellar disorders conventional MRI volumetry has been used to assess the correlation of behavioral data and regional cerebellar atrophy. Voxel-based morphometry (VBM) is an alternative with the potential for better spatial resolution. VBM is particularly appropriate in disorders with no obvious abnormalities in structural MRI (Rorden and Karnath, 2004). As yet, few studies have explored VBM as a tool to compare behavior and lesion site in patients with degenerative cerebellar disease (Lasek et al., 2006).

In the first part of this review the pros and cons of available human cerebellar lesion conditions will be discussed. In the second part examples of lesion-symptom mapping both in focal cerebellar disorders and cerebellar degeneration will be given.

HUMAN CEREBELLAR LESION CONDITIONS

In principle, lesions need to be exclusively restricted to the cerebellum in order to infer possible cerebellar function based on lesion localization and volume. However, patients with lesions restricted to the cerebellum are rare and it can be argued that there are no patients with 100% pure cerebellar lesions. Yet, several conditions lead to lesions that primarily affect the human cerebellum. In general three patient groups can be distinguished: patients with focal lesions due to stroke, patients with focal lesions due to tumors, and patients with slowly progressive degenerative disorders. Each of the available human cerebellar lesion conditions has its specific limitations, which will be discussed below (see Table 1 for summary).

Structural MRI makes it possible to exclude patients with extracerebellar involvement of the CNS, such as additional lesions of the brainstem in subjects with cerebellar stroke or degenerative disorders. Cranial MRI, however, cannot detect concomitant disorders of the peripheral nervous system or spinal cord. For example, many patients with cerebellar degeneration show mild accompanying signs of polyneuropathy in the lower limbs. Additional clinical and electrophysiological measures are required in order to reach definitive conclusions.

Cerebellar stroke

Patients with cerebellar stroke provide the only human lesion condition where symptoms can be studied following an acute lesion in a previously healthy cerebellum. Although tumor surgery causes an acute cerebellar lesion, the growing tumor has caused cerebellar dysfunction for an unknown time. Infarction of the cerebellum is a rare event representing up to 15% of all cerebral strokes (Tohgi et al., 1993; Amarenco, 1991; Weimar et al., 2002). First with the introduction and later with better availability and quality of CT and MRI scanners the number of detected cerebellar infarcts has increased. Furthermore, it became clear that the “classical” cerebellar ischemic syndromes including brainstem signs as well as life-threatening brainstem compression and hydrocephalus from postinfarct edema are comparatively rare (Kase et al., 1993; Chaves et al., 1994). The majority of cerebellar infarctions have a benign clinical course.

The main cerebellar arteries are the posterior inferior cerebellar artery (PICA), the anterior inferior cerebellar artery (AICA), and the superior cerebellar artery (SCA) (Caplan, 1996). Branches of the PICA supply the inferior aspects of the cerebellar hemispheres and inferior vermis extending up to the primary horizontal fissure. Branches of the AICA supply the flocculus, and adjacent lobules of the inferior and anterior cerebellum and the middle cerebellar peduncles. The SCA supplies the superior parts of the cerebellum down to the horizontal fissure. It supplies all cerebellar nuclei and most of the cerebellar white matter. In some cases the PICA supplies parts of the dentate nucleus. The SCA and PICA have two main branches, supplying the more dorsomedial (mPICA, mSCA) and the more ventrolateral (lPICA, lSCA) parts of each territory. Medial branches supply mostly the vermis and paravermian parts of the hemispheres, and lateral branches the more lateral parts of the hemispheres. The cerebellar vascular territories are nicely illustrated in Tatu et al. (1996) based

Author's personal copy

Table 1. Summary of pros and cons of available human cerebellar lesion conditions

Cerebellar disorder	Useful conditions	Not useful conditions	Pros	Cons	Necessary clinical assessments
Cerebellar stroke	Stroke within the territory of: - medial, lateral branches of PICA - medial, lateral branches of SCA	Stroke within the territory of AICA (commonly brainstem affection)	Only condition which permits lesion-symptom mapping in acute stage Good chronic lesion condition	Acute lesions: area showing structural changes may be smaller than area with functional changes - disconnection syndromes Old age	Cranial MRI and neurological examination to exclude brainstem and cerebral involvement
Cerebellar tumors	Benign tumors: - pilocytic astrocytoma in children and adolescents - hemangioblastoma and AVM in young adults	Malign tumors (radiation, chemotherapy): - medulloblastoma in children and adolescents	Young age Good chronic lesion condition	Lesion-symptom mapping before tumor removal and in acute postsurgical stage not feasible (mass effects) Effects of developing brain Effects of increased intracranial pressure Secondary changes in chronic lesions	Cranial MRI to exclude hydrocephalus Cranial MRI and neurological examination to exclude brainstem and cerebral involvement
Degenerative disease	ADCA III: SCA6 SAOA Very rare: ADCA III: SCA5, SCA11, SCA15, SCA16, SCA22(?), SCA26, SCA16q22-linked Individual cases: SCA8, SCA14 EA2	ADCA I: SCA1,2,3 ADCA I (rare): SCA4, 8, 10, 12, 13, 14, 17, 18, 19, 20, 21, 23, 24, 25, 27, 28 ADCA II: SCA7 MSA-C	Many laboratories have best access to this patient population	Old age Frequently mild extracerebellar involvement Diffuse and progressive nature of the disease SAOA may progress into MSA-C	MRI and neurological examination to exclude brainstem and cerebral involvement Neurological/electrophysiological testing to exclude involvement of peripheral nervous system, spinal cord and brainstem: nerve conduction studies, magnetic evoked potentials, somatosensory evoked potentials
Other	Viral cerebellitis Paraneoplastic cerebellar degeneration	Alcoholic cerebellar degeneration (alcoholism, polyneuropathy, cerebral atrophy)	Subacute lesions	No changes in MRI at acute stage Paraneoplastic: underlying malign disorders Viral cerebellitis: frequently benign course and good recovery	MRI and neurological examination to exclude brainstem and cerebral involvement

ADCA type I, with significant extracerebellar involvement; ADCA type II, with visual loss; ADCA type III, “pure” cerebellar syndrome.

Author's personal copy

on pathological studies by Amarenco (1991) and the injection studies by Marinkovic et al. (1995).

SCA and PICA infarcts are most common and occur with similar frequency (about 40% each; Caplan, 1996). AICA infarcts are rare (about 10%). Whereas PICA and SCA infarcts are frequently restricted to the cerebellum, AICA territory infarcts almost always include the lateropontine area and brainstem signs predominate (Amarenco and Hauw, 1990; Amarenco et al., 1993; Barth et al., 1993). Symptoms and signs differ depending on the vascular territory and are in good accordance with the known functional compartmentalization within the cerebellum (Diener and Dichgans, 1992). Oculomotor signs (nystagmus) are more common in mPICA compared to lPICA and SCA infarction (Amarenco et al., 1990; Barth et al., 1994). Ataxia of stance and gait are more severe in medial superior cerebellar artery branch (mSCA) and mPICA compared to lateral SCA branch (lSCA) and lPICA infarction (Amarenco et al., 1991; Sohn et al., 2006). Dysarthria is a sign of mSCA infarction (not PICA), limb ataxia a sign of infarction of the lateral branches of SCA and PICA. In a recent study, limb ataxia in PICA infarction has been related to additional damage in branches of the proximal intracranial territory supplying the inferior cerebellar peduncle, one of the important input structures of the cerebellum, or to damage in the relevant output structure, the interposed or dentate nuclei (Deluca et al., 2007). This would imply that lesions of the body representation in the posterior lobe of the cerebellum are not followed by limb ataxia.

In sum, patients with lesions in the medial and lateral branches of the PICA and SCA territories are a suitable condition to study lesion-symptom mapping in the cerebellum. Lesion effects on brainstem and the possibility of accompanying cerebral vascular disease need to be excluded, but often the lesions are relatively pure. SCA and PICA patients tend to be more restricted to the cerebellum, while AICA infarcts are rare and commonly affect the brainstem.

Cerebellar tumors

While patient availability may require the pooling of subjects with cerebellar ischemic lesions and cerebellar tumors, one needs to recognize several caveats that may limit the usefulness of pooling (Anderson et al., 1990). The first caveat concerns the age of the patient population. Whereas ischemic stroke is typically a disease of late adulthood, benign cerebellar tumors occur most frequently in children (ca. 75%; Rashidi et al., 2003). Primary brain tumors occur in children mostly within the cerebellum and in adults mostly in the cerebrum. Furthermore, unlike the adult situation where brain tumors are most often malignant primary or secondary neoplasms, in children at least half of the brain tumors are benign.

The most frequent tumors in the cerebellum in adults are metastases. These patients are unsuitable for human cerebellar lesion studies. Their general condition is commonly poor, and life expectancy is significantly reduced. In patients with cerebellar metastases the median survival rate is 5–8 months (Pompili et al., 2008). Furthermore, even in patients with solitary resectable lesions, surgery is followed by whole brain radiotherapy.

One pathology in young adults that does admit study are benign, non-invasive vascular tumors, in particular hemangioblastomas (World Health Organization [WHO] grade I), both sporadic or as part of Hippel-Lindau disease, and arteriovenous malformations (AVMs) of the cerebellum (Conway et al., 2001). The majority of hemangioblastomas occur within the cerebellar hemispheres, whereas AVM malformations more frequently affect the cerebellar vermis. Symptoms are due to mass effect in hemangioblastoma, and hemorrhage in AVM (Batjer and Samson, 1986; Matsumura et al., 1977; George et al., 1992). However, these conditions are rare and a large group of subjects is usually difficult to amass without the close cooperation of a specialized center.

In children, the most frequent cerebellar tumors are pilocytic astrocytomas (WHO grade 1; ca. 35%–40%) and medulloblastomas (ca. 40%; Campbell and Pollack, 1996; Desai et al., 2001; Rashidi et al., 2003). For the study of cerebellar function the investigation of patients with benign astrocytomas is much preferred. Complete surgical removal of the tumors cures the disease in the majority of cases. For malignant medulloblastoma, however, additional chemotherapy and radiation are needed with known detrimental effects on brain function particularly in young children.

Findings in these patients may be confounded by ongoing CNS maturation. Although most postnatal development of the cerebellum takes place within the first year or two of life and the cerebellum reaches adult size 4–7 years of age (Giedd et al., 1996), myelinization continues at a slow rate in subsequent years most likely until young adulthood (Pfefferbaum et al., 1994). The sequence of myelinization, however, is thought to follow the order of phylogenetic development (Vogt, 1905). Older parts of the cerebellum (that is archi- and paleocerebellum) probably complete myelinization earlier than newer parts (that is neocerebellum) (Jernigan and Tallal, 1990).

Apart from age, a second difference between tumor pathologies and ischemic stroke is that benign cerebellar tumors grow slowly, whereas acute stroke has an acute onset. In pilocytic astrocytomas, symptoms often progress insidiously during a period of months, or, in some cases, years, before diagnosis. This allows compensation to take place. In fact clinical presentation typically involves signs of increased intracranial pressure including headache, vomiting and papilledema. Cerebellar signs are less frequently present at the time of diagnosis. Often, ataxia only manifests after removal of the tumor, possibly due to the acute surgical lesion.

In order to perform lesion-symptom mapping in tumor patients, it is best to test behavior after surgical removal of the tumor. Because many cerebellar tumors cause symptoms due to mass effects (for example due to accompanying cysts in pilocytic astrocytoma and hemangioblastoma), exact lesion site is difficult to determine with the tumor still in place. Furthermore, mass effects may cause accompanying hydrocephalus. The long-term effects of

Author's personal copy

hydrocephalus and sudden surgical decompression are difficult to control.

A third difference between tumors and ischemia strokes is lesion localization. Cerebellar astrocytomas involve the vermis and cerebellar hemispheres with approximately equal frequency (Zuzak et al., 2008). In contrast with ischemic strokes, which affect both superior and inferior parts of the cerebellum, tumors are most frequently located within the posterior lobe. For example cerebellar dysarthria, known to be caused by lesions of the superior paravermal area (mSCA territory), is a rare clinical sign in children with cerebellar astrocytomas (Richter et al., 2005a).

In summary, young adults who have had operations on pilocytic astrocytomas in childhood or youth are a good option to study lesion-symptom mapping in the cerebellum. Younger and otherwise healthy subjects are an advantage compared to the majority of ischemic stroke patients. However, effects of increased intracranial pressure and a slowly growing lesion with subsequent removal in a still maturating brain complicate interpretation and are difficult to control. Young adults with removal of benign vascular tumors provide another possible condition, but patients are very rare.

Acute versus chronic focal lesions

Studies are most commonly performed in patients with chronic focal lesions. Studies in patients with acute cerebellar lesions imply a prospective study design (that is, the study must be designed before the subject pool is determined and then patients collected as they become available). Because patients are rare, data need to be collected over the course of a couple of years unless studies are performed in multiple centers simultaneously. Additionally, the site of the lesion is more difficult to define in acute than in chronic patients. This is particularly true in surgical lesions. In acute surgical lesions, there is usually a significant shift in neuronal structures because of edema, air and cell detritus. This causes overestimation of the extent of the lesions. Then, spatial normalization of the MRI data is difficult because individual landmarks are not stable after surgery. Furthermore, edema causes difficulty in differentiating between the effects of permanent and temporary lesions.

Edema and shift of anatomy are usually not a problem in acute stroke. In acute stroke, however, special MRI sequences are needed to show the full extent of the lesion. High-resolution T1-weighted MR images, for example magnetization-prepared rapid-acquired gradient echo sequence (MPRAGE), are most commonly used to define focal brain lesions. In very early stages, lesions may only be visualized on diffusion weighted imaging (DWI) or fluid attenuated inversion recovery (FLAIR) images (Wintermark et al., 2008). DWI allows good prediction of final infarct size. In the acute stage, however, some areas are structurally intact but not functioning normally. Here, perfusion MRI is helpful. This, however, requires injecting gadolinium during MRI scans or applying arterial spin labeling to use the blood itself as a contrast agent (Rorden and Karnath, 2004).

Furthermore, both in acute ischemic and surgical lesions, distant regions not affected by the structural lesions might suffer impaired function because of sudden loss of input. Single photon emission computed tomography or positron emission tomography allows visualization of disconnected areas, but because they are invasive techniques, they are rarely available. In the future, diffusion tensor imaging (DTI) may provide information about disconnected areas.

Lesion extent is much easier to define in chronic lesions using high-resolution T1-weighted MR images. The drawback is, however, that plastic changes have occurred and behavior is confounded by compensatory effects. In addition, secondary changes, such as focal cerebellar cortical atrophies following surgical lesions, can also occur.

Cerebellar (cortical) degeneration

Only a subset of hereditary, nonhereditary and acquired degenerative ataxias is considered “pure” cerebellar disorders (Klockgether, 2008). The neuropathological hallmark is cerebellar cortical degeneration, mostly affecting the Purkinje cell layer (Sasaki et al., 1998; Yang et al., 2000). Although some degenerative disorders affect the cerebellar nuclei (e.g. dentate nucleus in Friedreich’s ataxia and spinocerebellar ataxia type 3, SCA3), these disorders affect various other parts of the nervous system. Because no effective treatment is yet available, study of these subjects is different from the study of patients with Parkinson’s disease: Effects of treatment and the search for de novo patients are not a concern. The degenerative cerebellar disorders are slowly progressive disorders. Ongoing cerebellar degeneration and development of compensatory mechanisms and reorganization in both cerebellar and cerebral areas are likely to progress simultaneously. Also, although these disorders are considered “pure” cerebellar disorders, mild extracerebellar signs can be found in some of the patients (Schöls et al., 2008).

As a rule of thumb, autosomal recessive ataxias (Friedreich’s ataxia, for example) present with significant extracerebellar involvement—mostly spinal cord degeneration and significant polyneuropathy—and should not be used in studies of cerebellar function. Prior to the introduction of genetic tests, the autosomal dominant ataxias had been classified by Anita Harding (1983) into three groups based on the phenotype: autosomal dominant cerebellar ataxia (ADCA) types I, II and III. The most common phenotype is ACDA type I which is accompanied by varying extracerebellar symptoms. ADCA type II is rare and accompanied by visual loss. The second most common form is ADCA type III which is a purely cerebellar syndrome. Although the Harding classification has been replaced by the genetic classification of spinocerebellar ataxias (SCA), it is still useful particularly in cases where genetic testing has been inconclusive. ADCA III, but not ADCA I and II, may be included in lesion studies. The most common SCAs are SCA1, 2, 3 and 6, which account for up to 75% of all SCA families (Klockgether, 2008) whereas SCA1, 2 and 3 are ADCA type I, SCA6 is the prototype of ADCA type III. Thus, patients with SCA1, 2, and 3 should be

Author's personal copy

excluded from lesion studies while SCA6 patients can be useful subjects for these studies.

For some other, rare forms, a benign course with a more cerebellar phenotype has been described as well: SCA5, SCA11, SCA15, SCA16, SCA22, SCA26 and SCA 16q22-linked (Klockgether, 2008; Schöls et al., 2008). SCA8 and SCA14 are considered ADCA type I, but individual patients may present with nearly pure cerebellar ataxia. These forms, however, are very rare, and standard genetic testing is available only for a subset. Therefore, these patients will only rarely be available for testing. Patients with episodic ataxia type 2 (EA2) are also rare, but can be used because they frequently develop permanent signs of cerebellar dysfunction during the course of the disease.

SCA6 is a disorder of late adulthood, with a mean age of onset of 50–60 years (30–70, mean 50), and it is not always purely cerebellar. A subset of patients develops mild signs of axonal polyneuropathy (pallhypesthesia) and pyramidal tract dysfunction (brisk tendon reflexes). Sleep disorders and mild dysphagia may also occur (Rüb et al., 2006). The same is true for sporadic adult onset ataxia (SAOA), which has a similar clinical and MRI presentation as SCA6 (Abele et al., 2007). In this case, family history and genetic testing are negative, and the underlying cause is unknown. It is likely that the diagnosis reflects heterogeneous conditions. SAOA has previously been named idiopathic cerebellar ataxia (IDCA) and idiopathic late-onset cerebellar ataxia (ILOCA). During the course of the disease, patients need to be carefully monitored for autonomic and extrapyramidal signs and the development of pontine atrophy and hyperintensities in the brainstem. A percentage of the patients develop multiple system atrophy type C (cerebellar type) (MSA-C) and need to be excluded from further behavioral studies.

Paraneoplastic cerebellar degeneration and viral cerebellitis may present with pure cerebellar degeneration. In contrast to the hereditary and nonhereditary degenerative ataxias, in these disorders degeneration is subacute with very little time for compensation and reorganization. Subjects are severely affected within days or weeks. In the acute stage, however, lesion-symptom mapping is limited because early brain scans do not reveal cerebellar atrophy. In paraneoplastic disorders testing can be further limited by the underlying malign disorder.

In sum, the most common “pure” cerebellar ataxias are SCA6, which is autosomal dominantly inherited, and SAOA. Although there are exceptions, these disorders commonly occur in the elderly. Other limitations (mild extracerebellar involvement in some patients) apply. In addition to MRI scans, neurophysiological examination (nerve conduction velocities, somatosensory evoked potentials, magnetic evoked potentials) is warranted.

CLINICAL ATAXIA RATING SCALES

In human lesion studies it of interest if a given behavior correlates with the overall severity of cerebellar ataxia. Clinical ataxia scores are helpful to get a general idea about the severity of the cerebellar disease. Because in the clinical literature there is a current interest in validation of ataxia rating scales available scales are discussed in more detail. At present the most widely used scale is the International Cooperative Ataxia Rating Scale (ICARS; Trouillas et al., 1997). This is a semiquantitative scale which is divided into four subscales assessing (i) postural and gait disturbances, (ii) limb movement disturbances, (iii) speech disorders and (iv) oculomotor disorders. Despite its frequent use, there have been no reports of validation trials until recently (Storey et al., 2004; Schmitz-Hübsch et al., 2006a; Schoch et al., 2007).

Interrater reliability and test–retest reliability have been shown to be high for total ICARS and all but one of its subscales (Storey et al., 2004; Schmitz-Hübsch et al., 2006a). Internal consistency has been reported to be generally good (Schmitz-Hübsch et al., 2006a; Schoch et al., 2007). The use of ICARS, however, has recently been questioned. In ICARS, score on certain items determines the rating in other items. Unless the examiner is well trained and instructions for each item are carefully read, this may give rise to contradictory results. More importantly, internal validity appears to be a problem in degenerative patients. Ideally, the rating results of ICARS should be determined by four factors that correspond to the four subscales in a factorial analysis. Schmitz-Hübsch et al. (2006a) applied ICARS in a large group of patients with various forms of SCAs. Four factors were found but the only factor that coincided with one of the ICARS subscales was the oculomotor subscale. We addressed this question using factorial analysis in a group of patients with focal lesions. Principal-component analysis revealed five distinct and clinically meaningful factors. These corresponded to the four ICARS subscales as well as the laterality of kinetic functions (Schoch et al., 2007).

Because of the problems with ICARS for the assessment of degenerative disorders Schmitz-Hübsch and coworkers (2006b) developed a new scale they called SARA (Scale for the Assessment and Rating of Ataxia). In its final form SARA has eight items: gait, stance, sitting, speech, finger chase, nose-to-finger, fast alternating hand movements, and heel-to shin test. In a large validation trial, again in patients with different SCA types, interrater reliability was high for total SARA and single items except for nose-to-finger left and heel-to-shin left. Test retest reliability was high. Factorial analysis revealed that results in each item were determined by a single factor. This suggests that SARA measures a common underlying construct: ataxia. SARA is easier to administer and the time to perform SARA is shorter than ICARS.

In sum, use of total ICARS appears to be justified both in focal and degenerative patients. Use of ICARS subscores is fully justified in patients with focal lesions. In our experience, ICARS appears more sensitive to describe mild cerebellar dysfunction, which is the case in many patients with chronic ischemic lesions. SARA on the other hand is easier to apply and is commonly performed within 10 min in patients with pure cerebellar disease. In patients with degenerative disease it is preferable compared to ICARS unless oculomotor function is of particular interest.

Author's personal copy

Timed tests are an alternative to clinical scales, and they are assumed to be more reliable. Furthermore, they provide quantitative, inherently continuous data more amenable to parametric testing. Two quantitative scales have been validated in patients with degenerative cerebellar disorders (Schmitz-Hübsch et al., 2008; Tezenas du Montcel et al., 2008).

LESION SYMPTOM MAPPING

Focal cerebellar lesions

Reports of lesion extent in most behavioral studies in focal cerebellar patients have been based on the visual inspection of diagnostic CT and MRI scans (Courchesne et al., 1994; Timmann et al., 1999). Some studies compared patients with lesions affecting the right and left cerebellum (Ravizza et al., 2006; Leggio et al., 2008), lesions affecting primarily the midline (vermis) or hemispheres (Riva and Giorgi, 2000; Steinlin et al., 2003) or those affecting either PICA or SCA territory (Exner et al., 2004). Very few studies, however, supported the behavioral work with high-resolution MR images while applying newer MRI analysis methods (Urban et al., 2003). This approach has been our primary focus recently, and the results will be reviewed in the following sections.

In brief, for every participant, a three-dimensional (3-D) volume of the cerebellum is acquired using a T1-weighted MPRAGE sequence (voxel size$=1.00\times1.00\times1.00$ mm^3) on a 1.5 T MR scanner. Lesions are manually traced on axial, sagittal and coronal slices of the non-normalized 3-D MRI data set and saved as region of interest (ROI) using the free MRIcro software (http://www.sph.sc.edu/comd/rorden/mricro.html). More recently, we have started to use the free MRIcroN software with the traced lesions being saved as volumes of interest (VOI; http://www.sph.sc.edu/comd/rorden/mricron/). As a necessary prerequisite for group comparisons, spatial normalization into a standard proportional stereotaxic space is needed. Individual volume of the lesion and complete 3-D MRI data sets are simultaneously spatially normalized into Montreal Neurological Institute (MNI) 152-space according to the masking technique described by Brett et al. (2001) using the current version of statistical parametric mapping (SPM) (http://www.fil.ion.ucl.ac.uk/spm/). MNI coordinate space approximately matches the Tailarach space and is widely used as a standard reference coordinate system for reporting results of functional and structural MRI studies. Because the process of spatial normalization is likely to introduce some errors in individual anatomy, particularly within the posterior fossa, the extent of individual lesions is also analyzed based on non-normalized data for each individual subject, using characteristic anatomical landmarks. Normalized regions of interest are manually adjusted if the normalization introduced spatial errors that would lead to incorrect localization. Currently, we are exploring the use of the spatially unbiased atlas template of the human cerebellum, which has been developed by Diedrichsen (2006) and is freely available as an SPM-toolbox.

The affected cerebellar lobules are defined with the help of the 3-D MRI atlas of the cerebellum introduced by Schmahmann et al. (2000), and affected nuclei with the help of the 3-D MRI atlas of the cerebellar nuclei introduced by our group (Dimitrova et al., 2002). These atlases are based on individual data and do not take interindividual variability into account. More recently probabilistic atlases of the cerebellar cortex and nuclei have been developed based on larger groups of subjects (Dimitrova et al., 2006; Diedrichsen et al., submitted for publication). In addition, MRI sequences are applied to directly visualize the cerebellar nuclei. In the past we acquired a 3-D axial volume of the cerebellum using a T2*-weighted sequence on a 1.5 T MR scanner. Because of high iron content, cerebellar nuclei can be seen as hypointensities. More recently, we started to use susceptibility weighted imaging (SWI). SWI appears to be more sensitive in younger subjects where iron content is lower than in older subjects (Maschke et al., 2004a).

Comparing lesion site in two groups of patients. There are different ways to make use of the ROIs (Rorden and Karnath, 2004). One possibility is to pool brain imaging data across predefined anatomical regions, another way is to group patients based on a cutoff value of a measured behavioral variable and use this criterion to group the lesion data. The simplest way is to create maps of lesion overlap across these predefined groups. Subtraction analysis can help to visualize anatomical trends in these situations. These analyses are useful for smaller groups of subjects.

Pooling brain images across predefined anatomical regions. We have used high-resolution MRI to define the exact lesion site and to group patients based on these findings, focusing on classical eyeblink conditioning (Gerwig et al., 2003). Most authors agree that some forms of plasticity develop in both cerebellar cortex and nuclei as a result of training (Christian and Thompson, 2003; Bracha, 2004; De Zeeuw and Yeo, 2005). There are, however, ongoing controversies about the relative contributions of cerebellar cortex and nuclei. Classical eyeblink conditioning has been shown to depend on the integrity of Larsell lobule HVI (cerebellar hemispheral lobule VI according to Larsell) and the interposed nucleus (Yeo et al., 1985; Krupa et al., 1993). Both lobule HVI and the cerebellar nuclei are commonly supplied by the SCA. Patients, most of them with focal lesions due to stroke, were grouped into those with lesions affecting the territory commonly supplied by the SCA (lobules I–Crus I) and those with lesions commonly supplied by the PICA (lobules Crus II to X). Patients in the SCA group were further subdivided according to whether lesions did or did not affect the interposed nuclei.

Eyeblink conditioning was significantly reduced on the ipsilesional side in subjects with lesions within the common territory of the SCA, but it was within normal limits on the contralesional side. In subjects with lesions restricted to the common territory of the PICA, no significant difference was found comparing eyeblink in the affected and unaffected sides. In affected patients, we found no difference between the effects of lesions affecting only the cerebellar

Author's personal copy

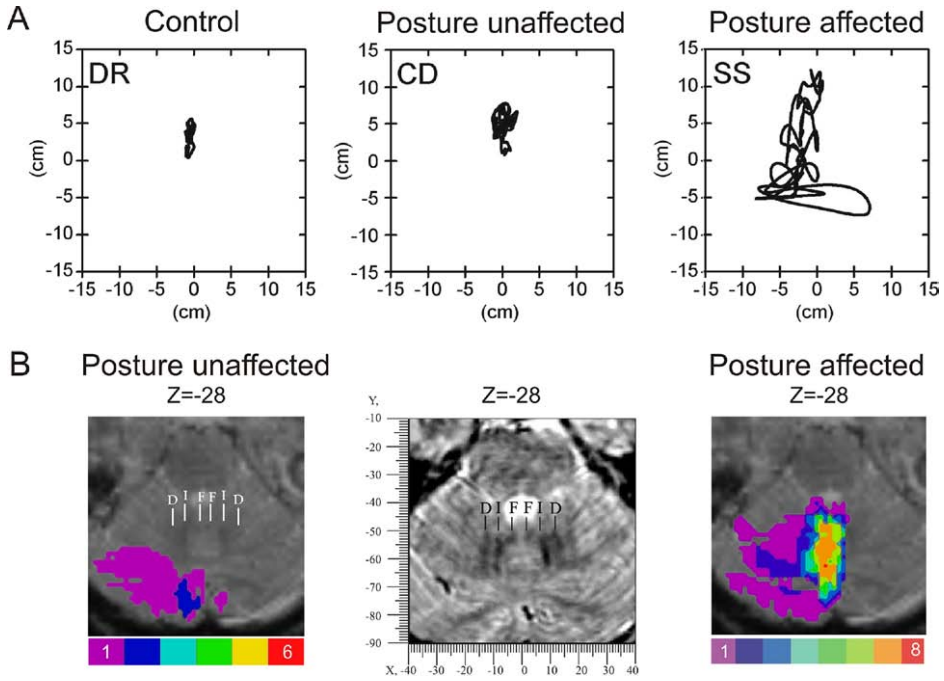

Fig. 1. Pooling brain images based on behavioral cutoffs (from Konczak et al., 2005). (A) Effect of nucleus fastigii lesions on postural sway. In patient CD the nuclei fastigii were intact, while lesioned in patient SS, who demonstrated excessive postural sway. Shown are the center of gravity sway paths over 20 s in one trial of a condition testing vestibulo(-cerebellar) function (platform sway-referenced, eyes closed). (B) Transverse views of the region of overlap in patients with intact posture (Posture unaffected) and in patients with abnormal sway area (Posture affected). Note: Colors represent the degree of overlap between patients (red indicating the highest overlap). Transversal section from 3-D MRI of the cerebellar nuclei (Dimitrova et al., 2002) is shown for comparison. Negative *z*-values correspond to distances in mm below the AC-PC (anterior commissure–posterior commissure) line. D, dentate nucleus; I, interposed nucleus; F, fastigial nuclei.

cortex or including the nuclei. These results corroborate findings described in earlier human literature (Woodruff-Pak and Steinmetz, 2000; Gerwig et al., 2007). Our data indicated that unilateral cortical lesions within hemispheric lobule VI or Crus I are sufficient to significantly reduce eyeblink conditioning in humans. Our results further suggest that the findings of functional divisions of the cerebellum in animals are transferable to humans. It is important to emphasize, however, that these findings do not speak against an additional role for the cerebellar nuclei.

Pooling brain images based on behavioral cutoffs. Another way to group patients is using behavioral thresholds. That is, we can define behavior as normal or abnormal according to comparisons with a neurological healthy control group and compare lesion sites between affected and unaffected patients. We took this approach in children and young adults with chronic surgical lesions. This study examined, whether lesions to the cerebellum obtained in early childhood are better compensated than lesions in middle childhood or adolescence (Konczak et al., 2005).

Postural sway was assessed in different conditions. All patients revealed normal sway kinematics during stationary platform conditions. However, in the two test conditions when platform tilt was sway-referenced and the eyes were closed or when vision was also sway-referenced, a subgroup of patients manifested excessive sway that could lead to falls or subjects stepping off the force plate. In these conditions subjects had to rely on vestibular inputs to maintain balance.

Eight of the 14 patients revealed abnormal postural sway. MRI overlays from these patients revealed that the lesioned areas involved the fastigial and interposed nuclei in eight of eight patients and dorsomedial portions of the dentate nucleus in six of eight patients (Fig. 1). In the remaining six patients, whose postural sway was within the limits of the control group, the region of maximum overlap was located in paravermal regions (VIIIA, VIIIB) and only included three of six patients. There was no correlation to lesion size, age at the time of the surgery or time since surgery. We concluded that the lesion site is critical for the motor recovery and lesions affecting the cerebellar nuclei are not fully compensated at any developmental age in humans.

In addition, these findings underscore the importance of fastigial nuclei (the medial zone) in postural control. However, not only the fastigial nuclei, but also the interposed nuclei and, to a lesser extent, the dorsomedial part of the dentate nucleus were affected. The dorsomedial part of the dentate is thought to be part of the intermediate zone (Mason et al., 1998). Behavior results cannot exclude the possibility that intermediate zone may contribute to balance. Lesion overlap did not include parts of the ventrolateral dentate nucleus. Thus, the results show that the lateral zone is unlikely to be involved in postural control.

Subtraction analysis. In a more recent study, we showed that disordered balance control during gait was equally associated with lesions affecting both the fastigial (that is medial zone) and interposed nuclei (that is inter-

Author's personal copy

mediate zone) (Ilg et al., 2008). All subjects had chronic surgical lesions and performed three tasks: Goal-directed leg placement, walking, and walking with additional weights on the shanks. Based on the performance in the first two tasks, patients were categorized as impaired (IL) or unimpaired (NIL) for leg placement and for dynamic balance (IB and NIB) control in gait. In addition to comparing lesion overlay plots in the two groups, a subtraction analysis was performed in MRICro (Karnath et al., 2002).

The lesions for all patients impaired in a given task (IB or IL, separate analyses) were added together, creating a traditional overlap image showing the regions of mutual involvement. Next, the lesions for the unaffected patients (NIB or NIL) were subtracted from the affected group's overlap image. Positive values indicate regions that are commonly damaged in IB (IL) patients, but that are spared in NIB (NIL) patients (Fig. 2). Negative values indicate the reverse situation: regions specifically damaged in the NIB (NIL) patients. Zero values indicate regions that are damaged in equal proportions in IB compared with NIB, and IL compared with NIL. Brighter shades of red, orange and yellow indicate positive values, and progressively brighter shades of blue illustrate negative values. Regions with a value of zero are shown in purple.

Subtraction of the ROIs of the six patients with impaired balance control and the six patients with unimpaired balance control, showed that the lower vermis and fastigial nuclei were affected 61%–80% more often in the impaired group (small area in light orange color in Fig. 2A). A more extended area could also be defined where lesions were 41%–60% more common in the affected group (red color). This area included the fastigial and interposed nucleus. Subtraction of the individual ROIs of the eight patients with IL and the four patients with NIL showed that dorsomedial parts of the dentate nucleus were affected 41%–60% more often in the impaired group (red color in Fig. 2B). Interposed nuclei were affected 21%–40% more frequently in the impaired group (middle brown).

Lesion-based MRI subtraction analysis revealed that the fastigial nuclei (and to a lesser degree the interposed nuclei) were more frequently affected in patients with impaired compared to unimpaired dynamic balance control, whereas the interposed and the adjacent dentate nuclei were more frequently affected in patients with IL compared to NIL. The subgroup with IL but not the subgroup with impaired balance showed abnormalities in the adaptation of locomotion to additional loads. A detailed analysis revealed specific abnormalities in the temporal aspects of intra-limb coordination for leg placement and adaptive locomotion. The intermediate zone appears thus to be of particular importance for multijoint limb control in both goal-directed leg movements and in locomotion. Further-

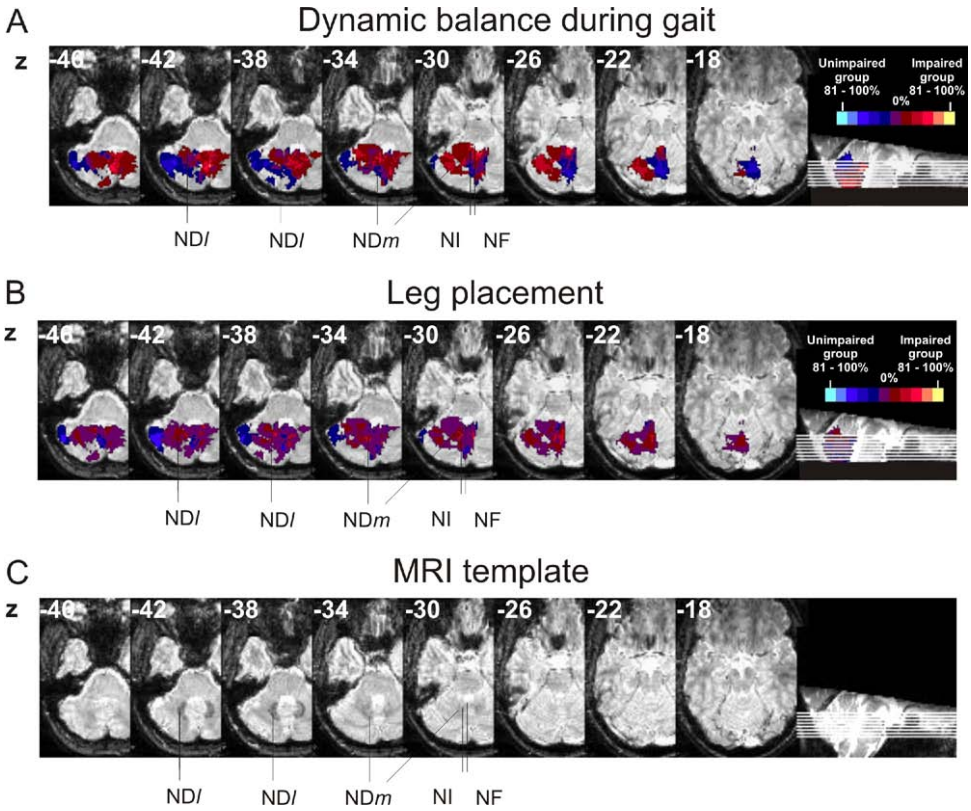

Fig. 2. Subtraction analysis (from Ilg et al., 2008). Subtraction of regions of interest (A) between patient groups with impaired and unimpaired dynamic balance in gait, and (B) between patient groups with impairment and unimpaired leg placement. Shown are transverse views. The percentage subtraction shows 11 levels of ROI: each bar represents 20% increments. Red represents 41%–60% impaired group. Regions affected to the same proportion in both patient groups are marked in purple (0%). (C) Cerebellar nuclei are shown as hypointensities in the utilized MRI template (from Dimitrova et al., 2002). NF, fastigial nucleus; NI, interposed nucleus; NDl, ventrolateral dentate nucleus; NDm, dorsomedial dentate nucleus.

Author's personal copy

more, lesions of the intermediate zone may lead to disordered leg and trunk coordination, which adds to disordered balance control during stance (Konczak et al., 2005) and gait (Ilg et al., 2008).

Voxel-based lesion symptom mapping (VLSM). In subtraction analysis no statistical comparison is performed. Voxelwise statistical mapping typically requires examining a relatively large group of patients. This is due to the inherent variability in lesion volume and extent as well as difficulties in computing the true structural and functional extent of a lesion (Rorden and Karnath, 2004; Rorden et al., 2007). A larger number of observations are required to survive multiple comparison correction. In our experience, 20 patients with focal cerebellar lesions are necessary to achieve reasonable statistical power.

When the symptoms are binary (for example a behavior is normal or abnormal based on a behavioral cutoff), binomial tests can be performed. For example, the free MRICro software includes a chi-square-test. In the newer MRIcroN software the Liebermeister test is offered as a substitute, which may be more sensitive (Rorden et al., 2007). If symptom severity is a continuous variable, multiple *t*-tests are more appropriate. In this case, correlation between tissue damage and behavior impairment can be obtained on a voxel-by-voxel basis without needing to group patients by either lesion site or behavioral cutoff. A *t*-test is conducted at each voxel comparing the behavioral scores of the patients for whom that voxel is intact and lesioned on the parameter of interest. This approach works best in chronic patients whose behavioral performance is stable. Following acute lesions, recovery takes place and differences in behavior may reflect the stage of recovery but not differences in lesion localization (Rorden and Karnath, 2004). Student's *t*-tests are implemented in free software developed by Stephen Wilson called VLSM (Bates et al., 2003; http://crl.ucsd.edu/vlsm/). It is now also available in the most recent versions of MRIcroN developed by Chris Rorden (Rorden et al., 2007; http://www.sph.sc.edu/comd/rorden/mricron/).

The *t*-test assumes that the data are normally distributed and is based on an interval scale. Although *t*-tests are robust to violations of these assumptions (the test loses sensitivity and does not generate false positives), nonparametric tests are preferred and frequently used in these situations. In MRIcroN the Brunner and Munzel test is offered as an alternative to *t*-tests (Rorden et al., 2007).

Student's *t*-tests. We applied VLSM (Bates et al., 2003) to correlate between clinical ataxia rating scores (ICARS; Trouillas et al., 1997) and MRI-defined lesions in patients with acute and chronic focal cerebellar lesions (Schoch et al., 2006). A total of 90 cerebellar patients were collected over a period of 6 years. Patients had either had a cerebellar ischemic stroke or they had undergone surgical removal of a cerebellar space-occupying process.

A separate analysis was performed in patients with acute and chronic vascular ischemic lesions and patients with acute and chronic surgical lesions. The generated VLSM map displays the *t*-scores where, by convention, large positive scores indicate that lesions in these voxels have a highly significant effect on behavior (that is lesioned patients perform poorly relative to intact patients). VLSM mapping of ICARS subscores revealed most robust statistical findings (max. value: 10.7, with P-value ≤ 0.05 to ≤ 0.0001, Bonferroni corrected) in acute ischemic patients, followed by chronic ischemic patients (max. t-value: 8.5 with $P \leq 0.05$ to ≤ 0.0001, Bonferroni corrected) and chronic surgical patients (max. t-value: 5.6 with $P \leq 0.05$ to ≤ 0.0001, not Bonferroni corrected). In contrast, no significant lesion–symptom correlation was observed in the acute tumor group for reasons outlined above (acute vs. chronic lesions).

In acute patients a somatotopy in the superior cerebellar cortex was found which is in close relationship to animal data and functional MRI data in healthy control subjects (Grodd et al., 2001). Upper limb ataxia was correlated with lesions of cerebellar lobules IV–V and VI (Fig. 3A), lower limb ataxia with lesions of lobules III and IV, and dysarthria with lesions of lobules V and VI. Urban et al. (2003) created maps of lesion overlap in patients with dysarthria due to acute stroke. In good accordance to our findings they showed dysarthria was related to lesions affecting the upper paravermal area of the cerebellar hemisphere.

Furthermore, in the acute lesions limb ataxia was significantly correlated with lesions of the interposed and part of the dentate nuclei, and ataxia of posture and gait with lesions of the fastigial nuclei including part of interposed nuclei. In the subgroups with chronic focal lesions, similar correlations were observed with lesions of the cerebellar nuclei, but no such correlations mentioned for the acute group with lesions of the cerebellar cortex (Fig. 3B). The lesion site therefore appears to be critical for motor recovery. The remaining cerebellar symptoms in both chronic ischemic and surgical cerebellar patients are significantly correlated with lesions of the cerebellar nuclei but not the cerebellar cortex. Findings support and extend results of our study using simple lesion overlay comparing young adults with and without remaining balance disorders following surgery at a young age (Konczak et al., 2005). Balance problems remained if the fastigial nuclei were affected (see above). The findings agree with animal studies showing that a recovery after lesions to the nuclei of the cerebellum is often less complete (Eckmiller and Westheimer, 1983).

In sum, comparison of lesion overlay plots comparing two groups of subjects based on behavioral cutoffs and subtraction analysis are helpful tools in smaller groups of subjects. In larger groups statistical methods can be applied. Examples are given which show that this method is useful to analyze function of the intermediate zone and the cerebellar nuclei in human subjects. Notably, these regions are not selectively affected in patients with focal lesions.

Cerebellar (cortical) degeneration

Study of patients with focal lesions offers much better spatial resolution than studies of patients with degenerative diseases. Furthermore, volumetry measures likely reflect cerebellar physiological dysfunction only in part. However, access

Author's personal copy

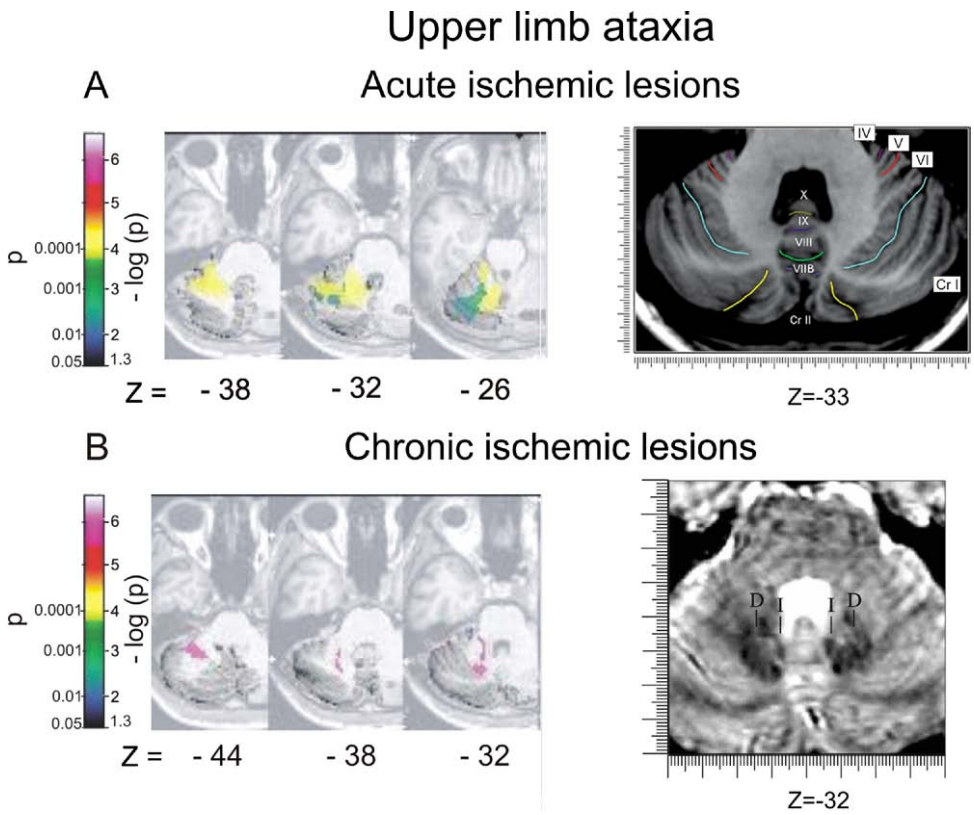

Fig. 3. VLSM (from Schoch et al., 2006). VLSM mapping (Bates et al., 2003) of upper limb ataxia rating score (ICARS; Trouillas et al., 1997) in (A) 21 subjects with acute and (B) 33 subjects with chronic ischemic cerebellar lesions. VLSMs are superimposed on axial slices of the cerebellum of a healthy subject normalized to MNI space. Right-sided lesions are flipped to the left. VLSM (*P*-values, Bonferroni corrected) maps are plotted with –log $P \geq 1.3$ and $P \leq 0.05$. Transversal sections from 3-D MRI atlas of the cerebellum (A; adapted from Schmahmann et al., 2000, page 150, copyright Elsevier) and 3-D MRI atlas of the cerebellar nuclei (B; Dimitrova et al., 2002) are shown for comparison. I, interposed nucleus; D, dentate nucleus.

to patients with degenerative cerebellar disorders is generally easier. Therefore, it is of interest if lesion-symptom mapping is possible despite the degenerative nature of the disease. Our studies show that this is the case.

Conventional cerebellar volumetry. We perform conventional brain volumetry. In brief, the same high-resolution 3-D T1-weighted MPRAGE scans (voxel size 1.0×1.0×1.0 mm^3) are obtained in the degenerative subjects as in focal cerebellar patients using a 1.5 T MRI scanner. In contrast with the studies in focal patients, MRI images are also obtained in the control group. The volumetric analysis of the MR images is performed using ECCET-software (http://eccet.acs.uni-duesseldorf.de/; Richter et al., 2005b; Dimitrova et al., 2006).

The cerebellum is semi-automatically marked and then segmented with a 3-D filling algorithm. Segmentation of cerebellar cortex and white matter is performed automatically using intensity contours (Makris et al., 2005). The primary fissure is manually defined on each scan and used to subdivide the anterior and posterior lobe (Fig. 4A). No reliable anatomical borders are available to subdivide the medial, intermediate and lateral zone. Therefore, separation of the three longitudinal zones is highly standardized. The examiner defines the midline of the cerebellum in the sagittal plane. The volume of 12 sagittal slices (six slices on the left and six on the right side of the midline) are considered medial zone. The remaining hemispheres are automatically divided into the intermediate and lateral cerebellum. The intermediate cerebellum is defined as the medial one quarter of the maximal width of each hemisphere; the lateral cerebellum comprises the lateral three-quarters (Luft et al., 1998). Volumes are assessed by two examiners. Interrater reliability is calculated. In our studies, interrater correlation coefficients are high (interrater correlation coefficients >0.8). Final volume measures are calculated as the mean of both examiners. For all statistical comparisons, cerebellar volumes are expressed as percentage of total intracranial volume (TICV). TICV includes brain and cerebrospinal fluid (CSF) volumes extending caudally to the foramen magnum.

Clinical ataxia scores. First, it was important to show that loss of cerebellar volume correlates with loss of cerebellar function (Brandauer et al., 2008). As expected, compared to the healthy subjects, patients had significantly smaller cerebellar volume, especially the volume of the medial cerebellum (vermis). Significant correlations between the cerebellar degeneration and both ICARS and SARA ataxia rating scores were found. Significant negative correlations between total cerebellum volume (Guerrini et al., 2004; Richter et al., 2005b) or cerebellar grey

Author's personal copy

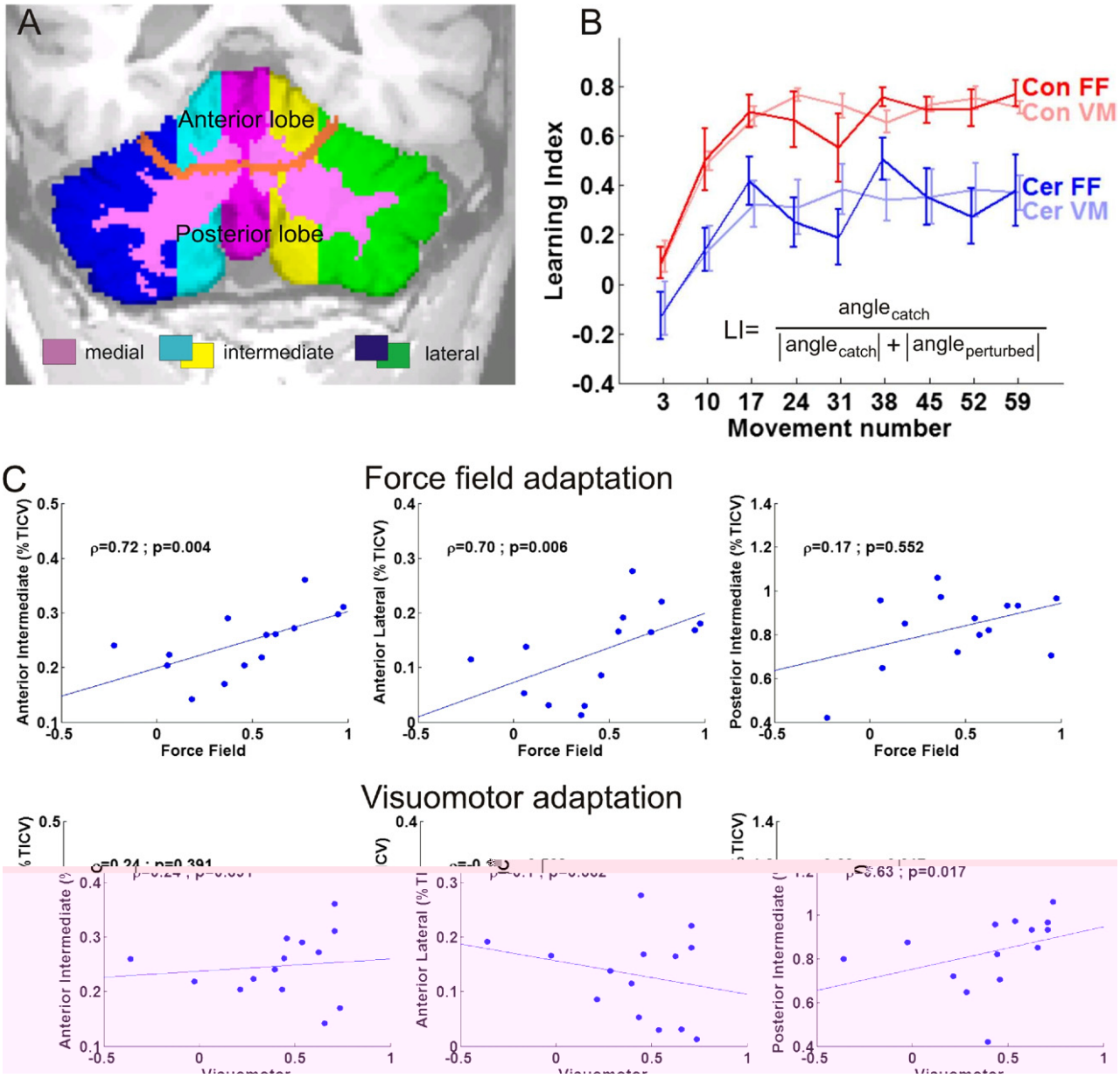

Fig. 4. Conventional cerebellar volumetry (from Rabe et al., 2009). (A) Illustration of the assessed cerebellar subvolumes. Grey matter volumes of medial (vermis; purple), left (blue) and right intermediate (yellow), as well as left (dark blue) and right lateral (green) cerebellum were quantified within the anterior and posterior lobe. White matter is shown in pink. Because movements were performed with the right arm, data of the right intermediate and lateral zones (grey and white matter) were entered into statistical analysis. Volumes are normalized to TICV (% TICV). Orange line=primary fissure. (B) Learning indices (LI) for the VM and FF task comparing patients with degenerative cerebellar disorders (Cer) and controls (Con). Error bars show ±1 standard error. Controls present significantly higher learning indexes during all movements. The LI were calculated as the ratio of the aiming error (AE) in catch trials without perturbation and the sum of the AE in both catch and perturbed trials. AE was taken as the angular deviation from baseline trajectories at maximal error. Thus, the LI lies between −1 and 1 with 1 indicating maximal learning and the range −1 to 0 indicating no learning. Bin size for calculating the LI was seven consecutive trials (six perturbed trials and one catch trial). (C) Correlations between mean LI of the VM and FF task and volumes of cerebellar subareas. A modified version of the Holm test was used to adjust for multiple testing.

matter (Brenneis et al., 2003; Lasek et al., 2006) and total ataxia scores have also been shown by others. Next, we tested if significant correlations between ataxia subscores and functionally meaningful cerebellar subvolumes could be observed. Oculomotor disorders were highly correlated with atrophy of the medial cerebellum. Posture and gait ataxia subscores revealed the highest correlations with the medial and intermediate cerebellar volume. Disorders in limb kinetic functions correlated with atrophy of lateral and intermediate parts of the cerebellum. The subscore for speech disorders showed the highest correlation with the intermediate cerebellum. All of these findings are consistent with animal data showing that the medial zone is of particular importance for control of stance, gait and eye

Author's personal copy

movements, and the intermediate and lateral zones for control of limb movements and speech (Lechtenberg and Gilman, 1978; Thach et al., 1992; Voogd and Barmack, 2005). Atrophy of the intermediate zone, however, was not only correlated with limb ataxia and dysarthria, but also with ataxia of stance and gait. This agrees with our group's studies in subjects with chronic focal cerebellar lesions cited above. These studies revealed that postural sway and disordered balance control during gait were associated with lesions affecting both the fastigial (medial zone) and interposed nuclei (intermediate zone) (Konczak et al., 2005; Ilg et al., 2008).

Adaptation to kinematic and dynamic errors. We have recently shown that lesion-symptom mapping in degenerative disorders can yield new insights regarding cerebellar function (Rabe et al., 2009). Cerebellar subjects are known to be impaired in adaptation to kinematic and dynamic errors. It is unclear, however, whether adaptation to kinematic and dynamic errors is processed by the same or different cerebellar areas. We investigated arm movements during visuomotor rotation (VM) and in a force field (FF) perturbation task in participants with cerebellar degeneration and matched controls. Patients suffered from SAOA ($n=8$), genetically defined cerebellar ataxia (SCA6, $n=3$; ADCA III, $n=2$) and chronic cerebellitis ($n=1$). In the VM task, movement of a two-joint manipulandum was shown on a monitor rotated 20° counterclockwise relative to the actual movement (that is to the left). In the FF task, a velocity dependent force (13 N/m/s times velocity) was applied perpendicular to the hand velocity by the motors, which pushed the manipulandum to the right. As expected, the cerebellar patients showed deficits in adaptation to both tasks when compared to controls (Fig. 4B) (Maschke et al., 2004b; Smith and Shadmehr, 2005; Tseng et al., 2007). However, we showed in addition that cerebellar deficits in one task were not significantly correlated to deficits in the other. Furthermore, atrophy of the intermediate and lateral zone of the anterior lobe correlated to impairment in the FF task while atrophy of the intermediate zone of the posterior lobe correlated to adaptation deficits in the visuomotor task (Fig. 4C). Our results suggest that adaptation to the different tasks is processed independently and relies on different cerebellar structures. Adaptation in these tasks is essentially predictive because we used a version of the task that does not allow feedback correction. Thus, our results indicate that the intermediate zone probably has predictive functions. This challenges the view that the lateral cerebellum, receiving input from cerebral cortex, is more involved in movement planning and that the intermediate cerebellum, receiving somatosensory input, plays a role in control of ongoing movements (Allen and Tsukahara, 1974; Evarts and Thach, 1969). Indeed, recent reviews by Bastian (2006) and Shadmehr and Krakauer (2008) have suggested that the intermediate cerebellum may well be involved in predictive control. In a different study, we also found results indicating that the intermediate zone is important for adaptation of gait (Ilg et al., 2008).

Voxel-based morphometry (VBM). VBM offers better spatial resolution and does not require a priori definition of functional relevant areas. Here, the relative grey and white matter concentrations for every voxel throughout the brain are estimated. Once each brain has been segmented into grey and white matter maps, we can analyze whether different experimental groups have different tissue concentrations. Indeed, VBM has been used in patients with SCA6 and has shown (the expected) grey matter loss (Lukas et al., 2006). More interestingly, correlation analysis between morphometric data and behavioral scores can be performed using a simple regression algorithm in SPM, and in a second step the corresponding correlation coefficient can be calculated for regions of interests. As yet, correlation analysis of VBM has rarely been used in cerebellar lesion studies. One reason is the issue of normalization, which is a prerequisite of VBM but not conventional MRI volumetry. A key issue is whether currently available normalization algorithms will work in patients suffering from severe morphological pathology such as cerebellar atrophy. However, one study has been published in patients with SCA17, which showed a meaningful significant negative correlation between ICARS and cerebellar structures (Lasek et al., 2006). The feasibility and usefulness of VBM need to be explored in future studies.

CONCLUSIONS

New advances in MRI technology and sequences as well as continually improving MRI analysis tools are proving helpful in investigating human cerebellar lesions and their relationship to behavioral deficits. Although studies of patients with focal lesions allow for better lesion localization, examining patients with degenerative disorders can also lead to meaningful results. Focal lesions studies can also lead to additional information about the function of the cerebellar cortex and nuclei. Application of new MRI techniques will improve definition of lesion extent even further. For example, signal-to-noise ratio increases with increasing field strength and allows spatial resolution in e it(7se)-y(it(7se)ngth

Author's personal copy

Kase CS, Norrving B, Levine SR, Babikian VL, Chodosh EH, Wolf PA, Welch KM (1993) Cerebellar infarction. Clinical and anatomic observations in 66 cases. Stroke 24:76–83.

Klockgether T (2008) The clinical diagnosis of autosomal dominant spinocerebellar ataxias. Cerebellum 7:101–105.

Konczak J, Schoch B, Dimitrova A, Gizewski E, Timmann D (2005) Functional recovery of children and adolescents after cerebellar tumour resection. Brain 128:1428–1441.

Krupa DJ, Thompson JK, Thompson RF (1993) Localization of a memory trace in the mammalian brain. Science 260:989–991.

Lasek K, Lencer R, Gaser C, Hagenah J, Walter U, Wolters A, Kock N, Steinlechner S, Nagel M, Zühlke C, Nitschke MF, Brockmann K, Klein C, Rolfs A, Binkofski F (2006) Morphological basis for the spectrum of clinical deficits in spinocerebellar ataxia 17 (SCA17). Brain 129:2341–2352.

Lechtenberg R, Gilman S (1978) Speech disorders in cerebellar disease. Ann Neurol 3:285–290.

Leggio MG, Tedesco AM, Chiricozzi FR, Clausi S, Orsini A, Molinari M (2008) Cognitive sequencing impairment in patients with focal or atrophic cerebellar damage. Brain 131:1332–1343.

Luft AR, Skalej M, Welte D, Kolb R, Bürk K, Schulz JB, Klockgether T, Voigt K (1998) A new semiautomated, three-dimensional technique allowing precise quantification of total and regional cerebellar volume using MRI. Magn Reson Med 40:143–151.

Lukas C, Schöls L, Bellenberg B, Rüb U, Przuntek H, Schmid G, Köster O, Suchan B (2006) Dissociation of grey and white matter reduction in spinocerebellar ataxia type 3 and 6: a voxel-based morphometry study. Neurosci Lett 408:230–235.

Makris N, Schlerf JE, Hodge SM, Haselgrove C, Albaugh MD, Seidman LJ, Rauch SL, Harris G, Biederman J, Caviness VS Jr, Kennedy DN, Schmahmann JD (2005) MRI-based surface-assisted parcellation of human cerebellar cortex: an anatomically specified method with estimate of reliability. Neuroimage 25:1146–1160.

Marinkovic S, Kovacevic M, Gibo H, Milisavljevic M, Bumbasirevic L (1995) The anatomical basis for the cerebellar infarcts. Surg Neurol 44:450–460.

Maschke M, Weber J, Dimitrova A, Bonnet U, Bohrenkämper J, Sturm S, Kindsvater K, Müller BW, Gastpar M, Diener HC, Forsting M, Timmann D (2004a) Age-related changes of the dentate nuclei in normal adults as revealed by 3D fast low angle shot (FLASH) echo sequence magnetic resonance imaging. J Neurol 251:740–746.

Maschke M, Gomez CM, Ebner TJ, Konczak J (2004b) Hereditary cerebellar ataxia progressively impairs force adaptation during goal-directed arm movements. J Neurophysiol 91:230–238.

Mason R, Miller LE, Baker JF, Houk JC (1998) Organization of reaching and grasping movements in the primate cerebellar nuclei as revealed by focal muscimol inactivations. J Neurophysiol 79:537–544.

Matsumura H, Makita Y, Someda K, Kondo A (1977) Arteriovenous malformations in the posterior fossa. J Neurosurg 47:50–56.

Pfefferbaum A, Mathalon DH, Sullivan EV, Rawles JM, Zipursky RB, Lim KO (1994) A quantitative magnetic resonance imaging study of changes in brain morphology from infancy to late adulthood. Arch Neurol 51:874–887.

Pompili A, Carapella CM, Cattani F, Fabi A, Giannarelli D, Giovannetti M, Mirri A, Occhipinti E, Telera S, Vidiri A, Pace A (2008) Metastases to the cerebellum. Results and prognostic factors in a consecutive series of 44 operated patients. J Neurooncol 88:331–337.

Rabe K, Livne O, Gizewski ER, Aurich V, Beck A, Timmann D, Donchin O (2009) adaptation to visuomotor rotation and force field perturbation is correlated to different brain areas in patients with cerebellar degeneration. J Neurophysiol, doi:10.1152/jn.91069.2008.

Rashidi M, DaSilva VR, Minagar A, Rutka JT (2003) Nonmalignant pediatric brain tumors. Curr Neurol Neurosci Rep 3:200–205.

Ravizza SM, McCormick CA, Schlerf JE, Justus T, Ivry RB, Fiez JA (2006) Cerebellar damage produces selective deficits in verbal working memory. Brain 129:306–320.

Richter S, Schoch B, Ozimek A, Gorissen B, Hein-Kropp C, Kaiser O, Hövel M, Wieland R, Gizewski E, Ziegler W, Timmann D (2005a) Incidence of dysarthria in children with cerebellar tumors: a prospective study. Brain Lang 92:153–167.

Richter S, Dimitrova A, Maschke M, Gizewski E, Beck A, Aurich V, Timmann D (2005b) Degree of cerebellar ataxia correlates with three-dimensional MRI-based cerebellar volume in pure cerebellar degeneration. Eur Neurol 54:23–27.

Riva D, Giorgi C (2000) The cerebellum contributes to higher functions during the development: evidence from a series of children surgically treated for posterior fossa tumors. Brain 123:1051–1061.

Rorden C, Karnath HO (2004) Using human brain lesions to infer function: a relic from a past era in the fMRI age? Nat Rev Neurosci 5:813–819.

Rorden C, Karnath HO, Bonilha L (2007) Improving lesion-symptom mapping. J Cogn Neurosci 19:1081–1088.

Rorden C, Fridriksson J, Karnath HO (2009) An evaluation of traditional and novel tools for lesion behavior mapping. Neuroimage 44:1355–1362.

Rüb U, Brunt ER, Petrasch-Parwez E, Schöls L, Theegarten D, Auburger G, Seidel K, Schultz C, Gierga K, Paulson H, van Broeckhoven C, Deller T, de Vos RA (2006) Degeneration of ingestion-related brainstem nuclei in spinocerebellar ataxia type 2, 3, 6 and 7. Neuropathol Appl Neurobiol 32:635–649.

Sasaki H, Kojima H, Yabe I, Tashiro K, Hamada T, Sawa H, Hiraga H, Nagashima K (1998) Neuropathological and molecular studies of spinocerebellar ataxia type 6 (SCA6). Acta Neuropathol (Berl) 95:199–204.

Schmahmann JD, Doyon J, Toga AW, Petrides M, Evans AC (2000) MRI atlas of the human cerebellum. San Diego: Academic Press.

Schoch B, Dimitrova A, Gizewski ER, Timmann D (2006) Functional localization in the human cerebellum based on voxelwise statistical analysis: a study of 90 patients. Neuroimage 30:36–51.

Schoch B, Regel JP, Frings M, Gerwig M, Maschke M, Neuhäuser M, Timmann D (2007) Reliability and validity of ICARS in focal cerebellar lesions. Mov Disord 22:2162–2169.

Schöls L, Linnemann C, Globas C (2008) Electrophysiology in spinocerebellar ataxias: spread of disease and characteristic findings. Cerebellum 7:198–203.

Schmitz-Hübsch T, Tezenas du Montcel S, Baliko L, Boesch S, Bonato S, Fancellu R, Giunti P, Globas C, Kang JS, Kremer B, Mariotti C, Melegh B, Rakowicz M, Rola R, Romano S, Schöls L, Szymanski S, van de Warrenburg BP, Zdzienicka E, Dürr A, Klockgether T (2006a) Reliability and validity of the international cooperative ataxia rating scale: a study in 156 spinocerebellar ataxia patients. Mov Disord 21:699–704.

Schmitz-Hübsch T, Tezenas du Montcel ST, Baliko L, Berciano J, Boesch S, Depondt C, Giunti P, Globas C, Infante J, Kang JS, Kremer B, Mariotti C, Melegh B, Pandolfo M, Rakowicz M, Ribai P, Rola R, Schöls L, Szymanski S, van de Warrenburg BP, Dürr A, Klockgether T (2006b) Scale for the assessment and rating of ataxia: development of a new clinical scale. Neurology 66:1717–1720.

Schmitz-Hübsch T, Giunti P, Stephenson DA, Globas C, Baliko L, Saccà F, Mariotti C, Rakowicz M, Szymanski S, Infante J, van de Warrenburg BP, Timmann D, Fancellu R, Rola R, Depondt C, Schöls L, Zdzienicka E, Kang JS, Döhlinger S, Kremer B, Melegh B, Filla A, Klockgether T (2008) SCA Functional Index: a useful compound performance measure for spinocerebellar ataxia. Neurology 71:486–492.

Shadmehr R, Krakauer JW (2008) A computational neuroanatomy for motor control. Exp Brain Res 185:359–381.

Shallice T (1988) From neuropsychology to mental structure. New York: Cambridge University Press.

Author's personal copy

Smith MA, Shadmehr R (2005) Intact ability to learn internal models of arm dynamics in Huntington's disease but not cerebellar degeneration. J Neurophysiol 93:2809–2821.

Sohn SI, Lee H, Lee SR, Baloh RW (2006) Cerebellar infarction in the territory of the medial branch of the superior cerebellar artery. Neurology 66:115–117.

Steinlin M, Imfeld S, Zulauf P, Boltshauser E, Lövblad KO, Ridolfi Lüthy A, Perrig W, Kaufmann F (2003) Neuropsychological long-term sequelae after posterior fossa tumour resection during childhood. Brain 126:1998–2008.

Storey E, Tuck K, Hester R, Hughes A, Churchyard A (2004) Interrater reliability of the International Cooperative Ataxia Rating Scale. ICARS. Mov Disord 19:190–192.

Tatu L, Moulin T, Bogousslavsky J, Duvernoy H (1996) Arterial territories of human brain: brainstem and cerebellum. Neurology 47: 1125–1135.

Tezenas du Montcel S, Charles P, Ribai P, Goizet C, Le Bayon A, Labauge P, Guyant-Maréchal L, Forlani S, Jauffret C, Vandenberghe N, N'guyen K, Le Ber I, Devos D, Vincitorio CM, Manto MU, Tison F, Hannequin D, Ruberg M, Brice A, Durr A (2008) Composite cerebellar functional severity score: validation of a quantitative score of cerebellar impairment. Brain 131:1352–1361.

Thach WT, Kane SA, Mink JW, Goodkin HP (1992) Cerebellar output, multiple maps and modes of control in movement coordination. In: The cerebellum revisited (Llinas R, Sotelo C, eds), pp 283–300. New York: Springer-Verlag.

Timmann D, Watts S, Hore J (1999) Failure of cerebellar patients to time finger opening precisely causes ball high-low inaccuracy in overarm throws. J Neurophysiol 82:103–114.

Tohgi H, Takahashi S, Chiba K, Hirata Y (1993) Cerebellar infarction. Clinical and neuroimaging analysis in 293 patients. The Tohoku Cerebellar Infarction Study Group. Stroke 24:1670–1697.

Trouillas P, Takayanagi T, Hallett M, Currier RD, Subramony SH, Wessel K, Bryer A, Diener HC, Massaquoi S, Gomez CM, Coutinho P, Ben Hamada M, Campanella G, Filla A, Schut L, Timmann D, Honnorat J, Nighoghossian N, Manyam B (1997) International cooperative ataxia rating scale for pharmacological assessment of the cerebellar syndrome. The Ataxia Neuropharmacology Committee of the World Federation of Neurology. J Neurol Sci 145:205–211.

Tseng YW, Diedrichsen J, Krakauer JW, Shadmehr R, Bastian AJ (2007) Sensory prediction errors drive cerebellum-dependent adaptation of reaching. J Neurophysiol 98:54–62.

Urban PP, Marx J, Hunsche S, Gawehn J, Vucurevic G, Wicht S, Massinger C, Stoeter P, Hopf HC (2003) Cerebellar speech representation: lesion topography in dysarthria as derived from cerebellar ischemia and functional magnetic resonance imaging. Arch Neurol 60:965–972.

Vogt O (1905) Die myelogenetische Gliederung des cortex cerebelli. J Psychol Neurol Bd V Heft 6:235–250.

Voogd J, Barmack NH (2005) Oculomotor cerebellum. Prog Brain Res 151:231–268.

Weimar C, Roth MP, Zillessen G, Glahn J, Wimmer ML, Busse O, Haberl RL, Diener HC; German Stroke Date Bank Collaborators (2002) Complications following acute ischemic stroke. Eur Neurol 48:133–140.

Wintermark M, Albers GW, Alexandrov AV, Alger JR, Bammer R, Baron JC, Davis S, Demaerschalk BM, Derdeyn CP, Donnan GA, Eastwood JD, Fiebach JB, Fisher, M, Furie KL, Goldmakher GV, Hacke W, Kidwell CS, Kloska SP, Köhrmann M, Koroshetz W, Lee TY, Lees KR, Lev MH, Liebeskind DS, Ostergaard L, Powers WJ, Provenzale J, Schellinger P, Silbergleit R, Sorensen AG, Wardlaw J, Wu O, Warach S (2008) Acute stroke imaging research roadmap. Stroke 39:1621–1628.

Woodruff-Pak DS, Steinmetz JE (2000) Past, present, and future of human eyeblink classical conditioning. In: Eyeblink classical conditioning, Vol. I. Applications in humans (Woodruff-Pak DS, Steinmetz JE, eds), pp 1–17. Norwell, MA: Kluwer.

Yang Q, Hashizume Y, Yoshida M, Wang Y, Goto Y, Mitsuma N, Ishikawa K, Mizusawa H (2000) Morphological Purkinje cell changes in spinocerebellar ataxia type 6. Acta Neuropathol (Berl) 100:371–376.

Yeo CH, Hardiman MJ, Glickstein M (1985) Classical conditioning of the nictitating membrane response of the rabbit. II. Lesions of the cerebellar cortex. Exp Brain Res 60:99–113.

Zuzak TJ, Poretti A, Drexel B, Zehnder D, Boltshauser E, Grotzer MA (2008) Outcome of children with low-grade cerebellar astrocytoma: long-term complications and quality of life. Childs Nerv Syst 24:1447–1455.

(Accepted 21 January 2009)
(Available online 27 January 2009)