46. Kumar P, Ahmed I. Pupil-sparing oculomotor palsy due to midbrain infarction [letter]. Arch Neurol 1992;49:348.
47. Kim JS, Kang JK, Lee SA, Lee MC. Isolated or predominant ocular motor nerve palsy as a manifestation of brainstem stroke. Stroke 1993;24:581-586.
48. Von Cramon D. Bilateral cerebellar dysfunctions in a unilateral mesodiencephalic lesion. J Neurol Neurosurg Psychiatry 1981;44:361-363.
49. Geller TJ, Bellur SN. Peduncular hallucinosis: MRI confirmation of mesencephalic infarction during life. Ann Neurol 1987;21:602-604.
50. Meienberg O, Mumenthaler M, Karbowski K. Quadriparesis and nuclear oculomotor palsy with total bilateral ptosis mimicking coma. A mesencephalic "locked-in syndrome"? Arch Neurol 1979;36:708-710.
51. Uematsu D, Suematsu M, Ebihara SI, Fukuuchi Y, Gotch F. Midbrain locked-in state with oculomotor subnucleus lesions. J Neurol Neurosurg Psychiatry 1985;48:952-953.
52. Bogousslavsky J. Syndromes oculomoteurs résultant de lésions mésencéphaliques chez l'homme. Rev Neurol (Paris) 1989;145:546-559.
53. Marshall RS, Sacco RL, Kreuger R, Odel JG, Mohr JP. Dissociated vertical nystagmus and internuclear ophthalmoplegia from a midbrain infarction. Arch Neurol 1991;48:1304-1305.
54. Ono S, Inoue K. Cheiro-oral syndrome following midbrain hemorrhage. J Neurol 1985;232:304-306.
55. Azouvi P, Tongeron A, Hussonois C, Schouman-Claeys E, Bussel B, Held JP. Pure sensory stroke due to a midbrain hemorrhage limited to the spinothalamic pathways. J Neurol Neurosurg Psychiatry 1989;52:1427-1428.

# The syndrome of 'cerebellar' mutism and subsequent dysarthria

Hugo R. van Dongen, PhD; Coriene E. Catsman-Berrevoets, MD, PhD; and Marijke van Mourik, MA

**Article abstract**—"Cerebellar" mutism refers to a specific childhood disorder in which a complete but transient loss of speech, followed by dysarthria, occurs after removal of a cerebellar tumor. We present a consecutive series of 15 children with this disorder, which we prefer to designate "mutism and subsequent dysarthria." The conditions in which it develops suggest also an extracerebellar component of cerebellar mutism. Hydrocephalus at presentation, localization of tumor adjacent to the fourth ventricle, and postsurgical edema of the pontine tegmentum are involved in its development.

NEUROLOGY 1994;44:2040-2046

In children, mutism frequently occurs after severe head injury[1] and in the acute stage of aphasia.[2,3] A number of studies focus on an intriguing clinical picture that occurs after removal of a cerebellar tumor, ie, mutism and subsequent dysarthria (MSD), commonly labeled "cerebellar" mutism. As of now, 36 cases are in the literature.[4-15] MSD is an iatrogenic complication usually occurring in children after removal of cerebellar medulloblastomas, astrocytomas, and ependymomas. The tumors are large and invade medial cerebellar structures. An associated hydrocephalus, edema, and postsurgical meningitis are regarded as risk factors for the mutism.[6,11] The literature confirms that 90% of the children with MSD are less than 10 years old.[4-15] The youngest patients described were 2 years old.[8,12]

The speech characteristics of the subsequent dysarthria are not delineated. The symptom of acquired dysarthria in children receives far less attention than that of acquired aphasia.[16-19] Often the symptom is described qualitatively only as "slurred, slow," and so forth. Attempts to elucidate cerebellar speech motor control are carried out mainly in adults. Based on a study of 122 patients, most with cerebellar tumors, Lechtenberg and Gilman[20] observed that dysarthria developed most frequently after damage extending into the paravermal segments of the left cerebellar hemisphere and, more specifically, into its superior portion. Amarenco et al[21] confirmed this in a patient with an isolated cerebellar dysarthria (aprosody with explosive staccato scanning speech) following a small infarction of the lobulus simplex and lobulus semilunaris superior in the left paravermal zone; they considered a minute mirror-image lesion to be of no importance. Ackermann et al[22] did not corroborate the notion of an exclusive left-sided paravermal cerebellar speech cortex; three of the four dysarthric subjects in their study had unilateral right-sided ischemia due to occlusion of the superior cerebellar artery. In one patient,[22] the lesion was very small and

See also pages 2001, 2047, and 2187

From the Department of Neurology (Drs. van Dongen and Catsman-Berrevoets, and M. van Mourik), University Hospital Rotterdam-Dijkzigt, Rotterdam, The Netherlands.

Presented in part at the biannual meeting of the European Federation of Child Neurology Societies, Berne, June 23-26, 1993.

Received October 4, 1993. Accepted in final form May 12, 1994.

Address correspondence and reprint requests to Dr. H.R. van Dongen, Department of Neurology, University Hospital Rotterdam-Dijkzigt, dr. Molewaterplein 40, 3015 GD Rotterdam, The Netherlands.

limited to the cerebellar cortex, leading the authors to conclude that the site of the lesion is more important than the size. In none of the speech-impaired patients in Ackermann's study could the dysarthria be classified as cerebellar.[23] Darley et al[23] proposed a cluster of the five most important features of cerebellar dysarthria in the following rank order of frequency: (1) imprecise consonants, (2) excess and equal stress, (3) irregular articulatory breakdown, (4) distorted vowels, and (5) harsh voice quality. Of these features, "excess and equal stress" and "irregular articulatory breakdown" are considered specific for cerebellar dysarthria. In contrast, "imprecise consonants" as a deviant speech dimension is aspecific because it is present in all other types of dysarthria. However, Kluin et al[24] do not completely agree with Darley's rank order. They[24] consider "excess and equal stress" and "articulatory breakdown" to be specific features as well, but add "alternating loudness," "variable rate," and "fluctuating pitch" as the other frequently occurring features.

We report on a consecutive series of 15 children in whom a posterior fossa tumor was removed. Our aim was (1) to determine the conditions under which MSD develops, (2) to analyze the features of the mutism and subsequent dysarthria, and (3) to define a more exact localization of the dysfunctional area of the nervous system related to the speech deficit.

**Methods.** In 3 years, 15 children with a diagnosis of posterior fossa tumor were surgically treated in our hospital. All children (10 boys and five girls, ages 2½ to 13 years) had normal psychomotor development. No speech problems immediately before admission had been observed by the parents. In all children, speech was assessed according to the "Mayo Clinic Lists" of Darley et al.[23] For rating the severity of the dysarthric components from videotaped samples of spontaneous speech, we used the University of Michigan rating system,[24] which extends from 0 (unaffected) to 3 (severely affected). Speech behavior was recorded on videotape before surgery, immediately after surgery, 3 days after surgery, and, in case of a speech disorder, every second week until recurrence of speech. In those patients, speech behavior was subsequently videotaped at intervals as short as possible for 2 to 4 weeks. The follow-up lasted until (nearly) complete recovery of speech (4 to 16 months).

Neurologic examination of the speech musculature was carried out according to the protocol for studying acquired childhood dysarthria.[17,19]

We divided the patients into three groups (table 1). Group A had no speech problems after surgery and consisted of eight patients. Group B (two patients) did not have mutism but did have mild speech problems after surgery. Group C consisted of five patients with mutism and dysarthria after surgery.

**Patient B1.** A 10-year-old boy was admitted with headache, vomiting, and 4 days of double vision. Neurologic examination was normal except for a position-evoked nystagmus. MRI (figure 1, B1) showed a tumor in the fourth ventricle, which was hypointense on $T_1$- and hyperintense on $T_2$-weighted images and enhanced homogeneously with gadolinium. The tumor invaded the right cerebellar hemisphere and the right cerebellar peduncle and extended by way of the foramen of Luschka into the right prepontine cistern. The tumor (ependymoma grade III) was macroscopically removed completely. After surgery, the boy obeyed simple commands but only started to speak 2 days after extubation. His voice was very soft, but no other speech abnormalities were heard. At neurologic and laryngoscopic examination, a right-sided paresis of the tongue, palatum, and vocal cords was observed. All symptoms disappeared within 2 weeks.

**Patient B2.** This 4-year-old girl presented with progressive trembling of the hands and insecure gait. At neurologic examination, she had a slight intention tremor of the hands and a mild ataxia of the limbs. On CT and MRI (figure 1, B2a and B2b), a very large extra-axial, partly calcified, contrast-enhancing tumor was visible, situated ventrally in the posterior fossa. On angiography, the tumor was situated anterior to the basilar artery and was fed from the meningeal truncus of the arteria pharyngea ascendens on the right side. In agreement with a diagnosis of meningioma, an intense tumor blush occurred. An attempt was made to embolize the solitary feeding artery after hyperselective catheterization, but this failed. At surgery, the greater part of a meningioma was removed. After surgery, the girl had a flaccid tetraparalysis and respiratory insufficiency for which full ventilation was required. She was alert and communicative. She could protrude her tongue past her teeth and carry out slow alternating movements of the tongue. Although she remained fully dependent on pressure-controlled ventilation, she answered questions by silently moving her lips, and she was able to whisper a limited number of words through a leaking cough. Five months after surgery, her clinical condition remained unchanged. On control MRI, ischemic lesions were present in the ventral part of the lower medulla (figure 1, B2c). Six months after surgery, she died of respiratory complications.

**Patient C1.** A 6-year-old boy presented with diplopia and progressive clumsiness. He had bilateral papilledema, a first-degree nystagmus in all directions, mild bilateral abducens pareses, and a slightly clumsy gait. CT (figure 2, C1) revealed a large mixed hypodense-hyperdense moderately enhancing tumor, partially occupying the fourth ventricle, and an associated hydrocephalus. After insertion of a VP shunt, the neurologic signs disappeared. For the first 24 hours after removal of the tumor (a medulloblastoma), the boy answered questions with three- to four-word sentences in a normal voice. He subsequently became increasingly apathetic and did not utter a word. The only sound he produced was a soft and continuous whining. He also did not try to communicate in any nonverbal way except after vigorous stimulation. He had difficulties with swallowing liquids and chewing food. He had a global pyramidal paresis of the right arm and leg and a severe bilateral limb and trunk ataxia (table 1). Paroxysmal tonic upward deviation of the eyes was noted. During the period of mutism, complex movements of the mouth were severely impaired, but no paresis of facial or pharyngeal musculature or of vocal cords was present (table 2). He started to recover complex movements of the mouth after 8 weeks postsurgery, which slowly improved to almost normal over the next 8 months. The ataxia and right-sided paresis gradually disappeared in the course of 8 months. CT 6 months after surgery showed a wedge-shaped surgical lesion in the midline of the cerebellum.

*Recovery of speech.* Quite unexpectedly, from 5 weeks after surgery on, he produced some phonemes, which at 7 weeks after surgery were laboriously uttered and unintelligible. Eight weeks after surgery, the child was able to re-

**Table 1. Clinical data of the patients from whom a posterior fossa tumor was removed***

| No. | Sex | Age (yr) | Tumor type | Lesion site | Cerebellar signs: Trunk | Cerebellar signs: Limb | Cerebellar signs: Oculo | Brainstem signs: Pyramidal tract | Brainstem signs: Cranial nerves |
|---|---|---|---|---|---|---|---|---|---|
| A. Patients without speech problems after surgery | | | | | | | | | |
| A1 | F | 11 | Astrocytoma I | L | (N) N | (+) + | (N) N | (+) N | (VI) N |
| A2 | M | 8 | Astrocytoma II | L | (N) + | (N) + | (+) N | (N) N | (II) II |
| A3 | M | 2 | Astrocytoma II | L | (N) ++ | (+) ++ | (N) N | (N) N | (VI) VI |
| A4 | F | 6 | Astrocytoma I | L | (N) + | (+) + | (N) N | (+) N | (N) N |
| A5 | M | 5 | Astrocytoma I | R | (N) N | (N) + | (N) N | (N) N | (II) II |
| A6 | M | 13 | Astrocytoma II | R | (N) N | (+) + | (N) N | (N) N | (N) N |
| A7 | F | 3 | Astrocytoma II | R | (++) ++ | (++) ++ | (+) + | (++) ++ | (II, VI) II, VI |
| A8 | M | 5 | Ependymoma II | L | (N) N | (N) + | (N) + | (N) N | (N) N |
| B. Patients with mild speech problems after surgery | | | | | | | | | |
| B1 | M | 10 | Ependymoma III | R | (N) N | (N) + | (+) N | (N) + | (N) IX, X, XII |
| B2 | F | 4 | Meningioma | NA | (N) N | (+) NA | (N) N | (N) ++ | (N) N |
| C. Patients with mutism and subsequent dysarthria after surgery | | | | | | | | | |
| C1 | M | 6 | Medulloblastoma | Medial | (N) ++ | (+) ++ | (+) ++ | (N) ++ | (VI) VI, XII |
| C2 | F | 8 | Medulloblastoma | Medial | (N) ++ | (+) ++ | (+) + | (N) ++ | (VI) VII, XII |
| C3 | M | 8 | Medulloblastoma | Medial | (N) ++ | (N) ++ | (N) + | (N) ++ | (VI) XII |
| C4 | M | 5 | Medulloblastoma | Medial | (N) ++ | (+) ++ | (+) N | (N) ++ | (N) N |
| C5 | M | 4 | Ependymoma II | R | (N) ++ | (N) ++ | (N) ++ | (N) ++ | (N) VII, XII |

* The results of neurologic examination before surgery (parentheses) and immediately after surgery (no parentheses) are presented.
L Left.
R Right.
NA Not applicable.
N No abnormalities.
\+ Mildly abnormal.
++ Severely abnormal.

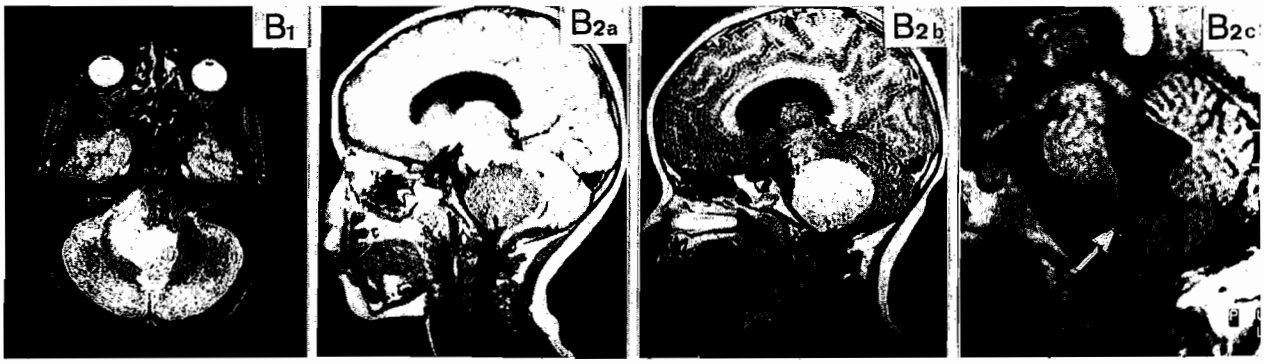


*Figure 1. MRI of the tumors of group B patients. B1 shows a transverse $T_2$-weighted image with long relaxation time of an ependymoma grade III. B2a and B2b show sagittal $T_1$-weighted images before (B2a) and after (B2b) enhancement with gadolinium of a posterior fossa meningioma in a 4-year-old girl. B2c shows a sagittal $T_1$-weighted image of the same patient after surgery. Note the extensive hypointense area of infarction in the ventral medulla (white arrow).*

peat not only words but also short sentences. He spoke with audible respiration {2} (numbers between braces indicate the severity of the dysarthric components according to Kluin et al[24]). His voice was hoarse {2} and nasal {2}, and its volume {2} rapidly decreased. The vowels were abbreviated when pronounced {2}, and consonants and clusters of consonants {3} caused severe articulation disturbance. His articulatory ability gradually improved, as did his voice and breathing, but 26 weeks after surgery, pronunciation of vowels {1} was still too brief. Clusters of consonants were laboriously and slowly uttered {2}. Sometimes a final sound was omitted {1}—for example, the "p" in the word "stop." Expiration was still audible {1}. He was able to maintain sufficient (but harsh) voice volume to complete the speech examination, which demonstrated a slow rate of speech {2}, pauses {1}, very mild nasality {1}, and monopitch {1}. Aphasic features such as paraphasias, neologisms, and syntactic errors were never noted. Language comprehension, as measured by the Test for Reception of Grammar,[25] was consistent with age.

**Patient C2.** An 8-year-old girl was admitted with headache, vomiting, diplopia, and gait disturbance. She had bilateral papilledema, abducens pareses, a paresis of up-

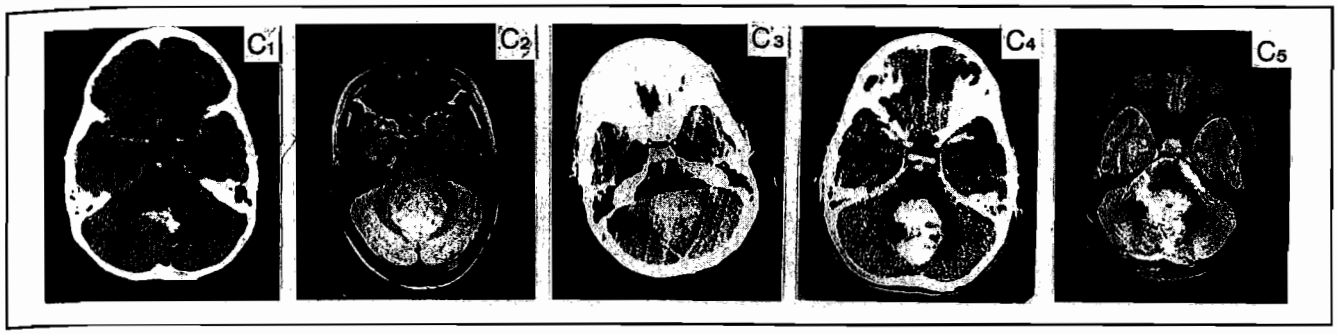


*Figure 2. Contrast-enhanced CT (C1, C3, and C4) and $T_2$-weighted MRI (C2 and C5) images of the tumors of the group C patients. Those in C1 through C4 are medulloblastomas. C5 shows an ependymoma grade II-III.*

**Table 2. Results of neurologic examination of lower cranial nerves during the initial stage of dysarthria**

| Symptom (cranial nerve) | Patient C1 | Patient C2 | Patient C3 | Patient C4 | Patient C5 |
|---|---|---|---|---|---|
| Trigeminal weakness (V m) | N | N | N | N | N |
| Sensation (V s) | N | N | N | N | N |
| Facial weakness (VII R/L) | N/N | N/++ | N/N | N/N | +/N |
| Pharyngeal weakness (IX) | N | N | N | N | N |
| Lingual weakness (XII) | | | | | |
| Tongue protrusion | + | + | + | + | + |
| L/R movements | N | + | + | + | + |
| Complex movements | | | | | |
| Alternating tongue movements | ++ | + | + | + | ++ |
| Clicking | ++ | + | N | N | ++ |
| Chewing | N | N | N | N | N |
| Swallowing | N | N | N | N | N |
| Blowing | ++ | + | N | N | + |
| Coughing | + | N | N | N | N |

m Motor branch. N No abnormalities.
s Sensory branch. + Mildly abnormal.
R Right. ++ Severely abnormal.
L Left.

ward gaze, first-degree nystagmus in all directions, and ataxia of the left arm and leg. CT and MRI (figure 2, C2) showed a large contrast-enhancing vermian tumor and hydrocephalus. A VP shunt was inserted, and in a second session a medulloblastoma was completely removed macroscopically. After surgery, a slight left hemiparesis was noted. Speech remained unremarkable until 2 days after surgery, when consciousness deteriorated. A posterior fossa epidural hematoma was diagnosed and evacuated. After removal of the hematoma, a left abducens and left peripheral paralysis of the facial nerve as well as a severe tetraparesis was observed. She produced a soft crying sound but did not talk. She was unable to move her tongue. Swallowing and complex movements of the mouth were impossible despite an intact seventh cranial nerve on the right side and intact ninth and tenth cranial nerves on both sides. She was severely apathetic but responded to questions adequately by squeezing with the right hand and, later, with the help of a signboard. In the following months, the limb pareses and the ataxia slowly subsided.

*Recovery of speech.* Four weeks after surgery she obeyed simple verbal commands but did not speak. Five weeks after surgery, laughing became audible {2} and sounded like hiccups. She was able to repeat a limited number of phonemes in a soft voice {3} but could not repeat monosyllabic words. After 8 weeks, the volume of her voice had increased {2}; she spoke with great effort and with alternating loudness {2}. Her voice was clear. She could shout only very softly {2} and trailed off into a dry cough. When she repeated phonemes and words, the vowels sounded flat {2}. Articulation was poor when repeating simple sentences, which she uttered very quickly. Clusters of consonants were still pronounced with difficulty {2}. Twelve weeks after surgery, her speech rate, as well as the prosody of spontaneous speech, were normal, but she still had mild articulatory difficulties in pronouncing clusters of consonants {1}. Aphasic disturbances were never observed.

Further follow-up was not possible because of neurologic deterioration due to multiple intracranial metastases of the medulloblastoma in the 20th week. She died 6 months after surgery.

**Patient C3.** An 8-year-old boy was admitted with headache after a minor trauma and 1 day of confusion. He was somnolent, and he had a right abducens paresis and bilateral papilledema. CT (figure 2, C3) showed a mixed hyperdense-hypodense contrast-enhancing vermian tumor and hydrocephalus. A VP shunt was inserted, and 4 days later a large medulloblastoma was almost completely removed. A film of tumor remained on the floor of the fourth ventricle. After surgery he spoke words in a normal voice. One day later, he ceased speaking, and a slight paresis of the right arm and severe ataxia of limbs and trunk was noted (table 1). CT and spinal fluid examination did not reveal a specific cause

for the deterioration. On the fourth day after surgery he developed pneumonia and a respiratory insufficiency for which he required full ventilation for 10 days. Two weeks after surgery, the VP shunt had to be removed because of infection. Three weeks later it was reinserted because of clinical complaints of raised intracranial pressure and widening of the ventricles on CT. One week after removal of the medulloblastoma, he obeyed simple commands. A further week later, after extubation, he was unable to speak but produced a soft crying sound. Chewing and swallowing were unimpaired (table 2). Four weeks after surgery he did not speak and could be stimulated to cooperate only with great effort. Communication was possible by means of a communication board. On request, the boy wrote the names of objects and answered yes or no to questions. During the period of mutism, the function of the cranial nerves was unimpaired, with the exception of poor tongue protrusion and lateral movements of the tongue. The duration of the mute period was 8½ weeks. When speech recurred, he had a moderately severe ataxia of trunk and limbs such that he could sit and walk with support.

*Recovery of speech.* On examination one day after he started to speak again, his voice was hoarse {3} and very soft {3}. Respiration was noisy {2}. Only with extreme effort could he produce monosyllabic words, in which the final phoneme was frequently omitted {2}. Ten weeks after removal of the medulloblastoma, his voice was louder and less hoarse {2}. He spoke spontaneously in sentences, in a monotonous {1} and nasal {1} way. There were many pauses {2} and forced inspiration and expiration {2}. The articulation of consonant clusters was imprecise {2}. Twelve weeks after surgery there was a strong increase in volume {1}. The pauses had decreased {1}, and inspiration and expiration {1} now matched his slow rate of speech {2}. Difficulties in producing consonant clusters {1} were apparent only when repeating polysyllabic words.

At follow-up 16 months after surgery, speech was normal except for a slow rate of speech, which was exclusively heard by his mother when he was tired.

**Patient C4.** A 5-year-old boy was admitted with early morning vomiting, diplopia, and staggering gait. Bilateral papilledema, a vertical skew deviation of the eyes, and a slight ataxia of the left arm and leg were found. On CT and MRI (figure 2, C4), a vermian tumor of mixed density, with some small calcifications and several cystic components filling up the fourth ventricle, and an associated hydrocephalus were observed. After insertion of a VP shunt only papilledema remained. In a second session, a medulloblastoma was macroscopically completely removed. Following surgery, he had a severe ataxia of trunk and limbs, and he was extremely apathetic. He spoke only a few words, after which he did not speak for 8 weeks. During this period he obeyed commands willingly, but he cried with a soft whining voice when he was stimulated to answer questions. Cranial nerves were intact except for lingual weakness (table 2). Complex movements of the mouth and tongue were impaired, but he had no problems with eating or drinking. Two weeks postsurgery, 3 × 5 mg bromocriptine was administered for 2 weeks, without any effect on recovery of speech.

*Recovery of speech.* Eight weeks after surgery he started to speak single words. His speech rate {3} was very slow; the words were "spelled" sound by sound with a strained-strangled voice {2}. Ten weeks after removal of the medulloblastoma, his voice was still strained-strangled {1}; sometimes it was sufficiently loud and on other occasions he whispered {2}. With great effort, he uttered a few words slowly. There was audible inspiration {2} when he repeated two- and three-syllable words. There were prolonged intervals and phonemes {2}. Three months after surgery, spontaneous speech was still severely limited. However, he was able to repeat sentences slowly. Phonemes were still prolonged {1}. After follow-up at 4 and 6 months, no abnormalities of speech were noticed except for a slightly slow rate of speech {1}.

**Patient C5.** A 4-year-old Moroccan boy had complaints of headache and early morning vomiting of 2 months' duration. The parents denied aberrant speech or walking pattern. He was admitted when he suddenly lost consciousness and showed extension spasms. On MRI (figure 2, C5) a large tumor was seen of mixed density on $T_1$- and $T_2$-weighted images, which enhanced in a nonhomogeneous manner with gadolinium. The tumor completely filled the fourth ventricle and extended into the right cisterna magna and dorsally along the medulla and spinal cord down to the level of C-2. Adherence of the tumor was noted at the mesencephalon at the level of the inferior colliculus and at the vermis cerebelli. There was a large proximal hydrocephalus. Consciousness cleared after insertion of a VP shunt. He had bilateral papilledema but no further neurologic abnormalities. After removal of the largest part of the tumor (ependymoma grade II-III), he answered questions and, according to his parents, spoke with a normal voice in his Berber dialect. He had a severe paresis of the limbs and a severe ataxia of the right arm. He could not sit unsupported. There was a slight right peripheral facial nerve paresis. He could bring his tongue past his teeth but could not lick his lips. One day after surgery, he became increasingly apathetic and stopped speaking. He developed a respiratory insufficiency for which ventilation was required for 4 days. After extubation, he did not utter any word for 3 weeks, but only whined and cried with a soft voice, especially when stimulated to speak. Lower cranial nerves were intact except for mild lingual weakness. Complex movements of the mouth were severely impaired (table 2). After 3 weeks he suddenly started to produce monosyllabic words, and within a few days he spoke in sentences of considerable length. Because of the language barrier, the speech could not be properly evaluated. However, the Dutch-speaking relatives described the language as fairly intelligible but slightly flaccid. During the mute phase, MRI showed a quadriventricular hydrocephalus and a hyperintense contrast-enhancing lesion in the mesencephalic and pontine tegmentum, more so on the left than on the right side (figure 3A). Measurements of intracranial pressure showed a low-pressure hydrocephalus. MRI 2 weeks after recurrence of speech showed that the hydrocephalus was diminished and the hyperintense lesion had disappeared (figure 3B). When speech recurred, ataxia was still severe.

**Results.** The clinical data of the patients are summarized in table 1. In the present series, none of the children was dysarthric before surgery. Five of 15 children—all with a tumor lining the fourth ventricle—developed MSD after surgery. They became mute after 1 to 2 days with normal speech. None of the children with a left or right cerebellar hemisphere tumor developed dysarthria or MSD, even when the superior paravermal cortical region was clearly involved in the process (patients A1, A3, A5, and A7). These patients all had astrocytomas, which may also cause MSD.[4,6,8,9,12,14] In all MSD children, we investigated

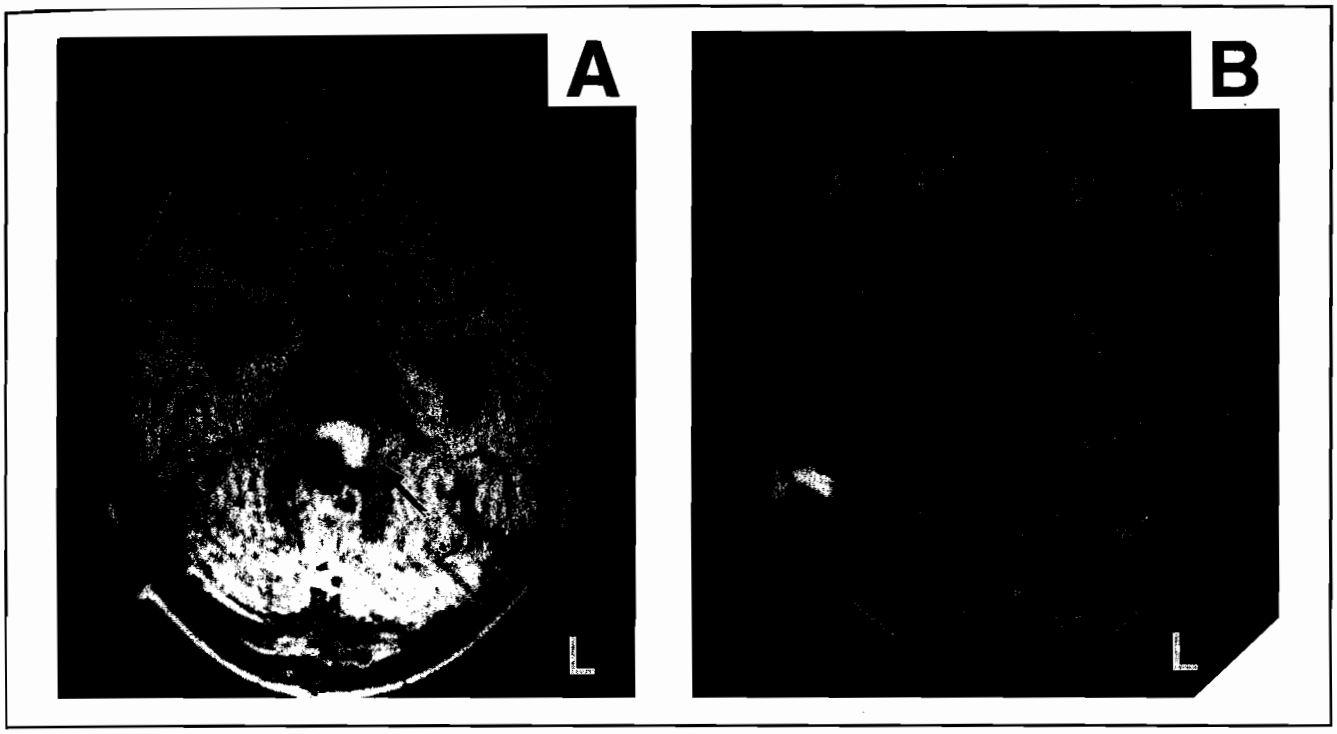


*Figure 3. $T_1$-weighted MRI of patient C5, 2 weeks (A) and 5 weeks (B) after resection of an ependymoma. Note hyperintense lesion (L > R) in pontine tegmentum in (A) (arrow), which is no longer present 3 weeks later (B).*

the speech musculature. No paresis of bulbar musculature was found in group A children. Patients B1 and B2 showed pareses of bulbar nerves. Only a mild weakness of the tongue was found in all MSD children, but complex movements of the speech musculature—for example, alternating movements of the tongue—were disturbed during the mute phase in all the children.

The length of the mute phase varied from 3 to 8½ weeks. In patient C4, treatment with high-dosage bromocriptine, a dopamine agonist, did not influence recovery. The recurrence of speech, even from the point of view of the parents, was unexpected in all the children. When they regained speech they were all severely dysarthric, but speech recovered to almost normal surprisingly fast in 1 to 5 weeks. In four of the five children with MSD, speech could be studied in detail. Only patient C2 had one mild ataxic speech characteristic. Recovery of dysarthria to normal speech seems to be related to recovery of complex movements of mouth and tongue.

In all three groups, the sizes of the tumors varied considerably. The largest tumors were not present exclusively in the MSD group. In the five MSD children, the tumor involved the inferior part of the vermis cerebelli (figure 2) with exophytic growth into the fourth ventricle. In patients C2, C3, C4, and C5, tumor completely filled the fourth ventricle and adhered to the floor of the fourth ventricle. Tumor growth through the inferior cerebellar peduncle onto the ventral surface of the brainstem was present in patients A8, B1, and C5, all with ependymomas.

Four of 10 children from groups A and B needed a VP shunt at presentation. In contrast, in all MSD children, a major hydrocephalus was present that needed shunting prior to tumor surgery ($p < 0.05$, Fisher's exact test). Patient C5 had a quadriventricular normal-pressure hydrocephalus after surgery, and patients C3 and A8 had a shunt infection and needed shunt revision after surgery.

In three of the five MSD children, MRI was performed during the mute phase. In patients C3 and C4, MRI 6 and 4 weeks postsurgery revealed no abnormalities except for the surgical cerebellar lesion. In patient C5, MRI 2 weeks after surgery revealed edema in the pontomesencephalic tegmentum involving the crossing fibers of the superior cerebellar peduncles (figure 3A). This edema had disappeared 3 weeks later, ie, 2 weeks after recurrence of speech (figure 3B). In contrast, after infarction of the ventral medulla oblongata in patient B2, no MSD occurred.

**Discussion.** We found that an isolated lesion of cerebellar structures caused by removal of a hemisphere tumor was not sufficient to produce MSD. An additional ventricular localization of tumor and adherence to the dorsal brainstem were necessary risk factors,[7,10,12] suggesting that brainstem dysfunction is important in the etiology of MSD. The obligatory postsurgical occurrence of MSD suggests that trauma is of importance in its evolution, possibly due to the more intense manipulation of the brainstem when the part of the tumor situated in the fourth ventricle or adhering to the dorsal brainstem is removed. Because of the transient nature of the syndrome, Ferrante et al[7] suggested ischemia and possibly edema as possible mechanisms. Edema in the pontine tegmentum in patient C5 during the mute phase supports this assumption.

The frequent occurrence of pyramidal and eye movement signs in MSD patients supports brainstem dysfunction. Neither exclusive cerebellar or brainstem lesions or hydrocephalus alone, but rather a complex interaction of these variables, causes MSD.

Unlike adults,[20-22] children do not suffer speech disturbance caused by damage to the superior paravermal cortical region, as patients A1, A3, A5, and A7 demonstrate. In these patients, whose CTs after surgery clearly showed either left- or right-sided damage to these regions, speech remained normal. Despite their normal speech, some of the children in group A were severely ataxic (patients A3 and A7), demonstrating the lack of strict relation between ataxia and speech disturbance.[23]

In view of the multifactorial origin of MSD, it is not expected that a "pure" cerebellar dysarthria will occur. The four patients of group C had a variety of speech characteristics. The most specific features of ataxic speech according to Darley et al,[23] which are "excess and equal stress" and "irregular articulatory breakdown," were met in none of those four patients. Only one (patient C2) had a specific feature of cerebellar speech (alternating loudness) according to Kluin et al.[24] The observed dysarthric features do not fit into any other cluster of deviant speech dimensions considered specific for a certain type of dysarthria.[23]

In patient B2, extensive infarction of the ventral medulla occurred without MSD. Because of the possibility of dysfunction of the ascending mesencephalofrontal fibers originating from the A9 and A10 dopaminergic cell groups causing MSD,[26-28] we administered bromocriptine to patient C4. The drug had no effect on the MSD.

The above observation as well as the finding of intact bulbar cranial nerves in patients who developed MSD suggest a localization of the brainstem dysfunction rostral to the medulla oblongata and caudal to the mesencephalon.

Summarizing our data and those in the literature, we conclude that MSD is a childhood syndrome with the following features: (1) occurrence between ages 2 and 10 years; (2) transient mutism of variable duration, followed by dysarthria that recovers quickly and completely; (3) bilateral dysfunction of the dentatothalamic fiber bundles or their cells of origin after surgical intervention in the posterior fossa as the proximate cause; and (4) a spectrum of neurologic manifestations, varying in severity, as a frequent accompaniment.

## Acknowledgments

We are grateful to Dr. M.C.B. Loonen, Dr. H.D. Paz y Geuze, and Dr. Janet A. Lees for the many helpful comments.

## References

1. Levin HS, Madison CF, Bailey CB, Meyers CA, Eisenberg HM, Guinto FC. Mutism after closed head injury. Arch Neurol 1983;40:601-606.
2. Alajouanine TH, Lhermitte F. Acquired aphasia in children. Brain 1965;88:653-662.
3. Martins IP, Ferro JM. Recovery of acquired aphasia in children. Aphasiology 1992;6:431-438.
4. Ammirati M, Mirzai S, Samii M. Transient mutism following removal of a cerebellar tumor. Childs Nerv Syst 1989;5:12-14.
5. Balasubramaniam C, Subramaniam V, Balasubramaniam V. Mutism following posterior fossa surgery for medulloblastoma. Neurol India 1993;41:173-175.
6. Dietze DD, Mickle JP. Cerebellar mutism after posterior fossa surgery. Pediatr Neurosurg 1990-91;16:25-31.
7. Ferrante L, Mastronareli L, Acqui M, Fortuna A. Mutism after posterior fossa surgery in children. J Neurosurg 1990;72:959-963.
8. Herb E, Thyen U. Mutism after cerebellar medulloblastoma surgery. Neuropediatrics 1992;23:144-146.
9. Hudson LJ, Murdoch BE, Ozanne AE. Posterior fossa tumor associated speech and language disorders post-surgery. Aphasiology 1989:3:1-18.
10. Humphreys RP. Mutism after posterior fossa tumor surgery. In: Marlin AE, ed. Concepts in pediatric neurosurgery. Basel: Karger, 1989.
11. Nagatani K, Waga S, Nakagawa Y. Mutism after removal of a vermian medulloblastoma: cerebellar mutism. Surg Neurol 1991;36:307-309.
12. Pierre-Kahn A, Mitjaville I, Debray-Ritzen P, Hirsch JF. Mutisme après chirurgie de la fosse postérieure chez l'enfant [abstract]. Rev Neurol (Paris) 1980;136:92.
13. Rekate HL, Grubb RL, Aram DM, Hahn JF, Ratcheson RA. Muteness of cerebellar origin. Arch Neurol 1985;42:697-698.
14. Volcan I, Cole GP, Johnston K. A case of muteness of cerebellar origin. Arch Neurol 1986;43:313-314.
15. Wisoff JH, Epstein FJ. Pseudobulbar palsy after posterior fossa operation in children. Neurosurgery 1984;15:707-709.
16. Aram DM, Rose DF, Rekate HL, Whitaker HA. Acquired capsular/striatal aphasia in childhood. Arch Neurol 1983; 40:614-617.
17. Bak E, van Dongen HR, Arts WFM. The analysis of acquired dysarthria in childhood. Dev Med Child Neurol 1983;25:81-94.
18. Echenne B, Gras M, Astruc J, Castan P, Brunel D. Vertebrobasilar arterial occlusion in childhood. Report of a case and review of the literature. Brain Dev 1983;5:577-581.
19. Van Dongen HR, Arts WFM, Yousef-Bak E. Acquired dysarthria in childhood: an analysis of dysarthric features in relation to neurologic deficits. Neurology 1987;37:296-299.
20. Lechtenberg R, Gilman S. Speech disorders in cerebellar disease. Ann Neurol 1978;3:285-290.
21. Amarenco P, Chevrie-Muller C, Roullet E, Bousser MG. Paravermal infarct and isolated cerebellar dysarthria. Ann Neurol 1991;30:211-213.
22. Ackermann H, Vogel M, Petersen D, Poremba M. Speech deficits in ischaemic cerebellar lesions. J Neurol 1992;239:223-227.
23. Darley FL, Aronson AE, Brown JK. Differential diagnostic patterns of dysarthria. J Speech Hear Res 1969;12:246-269.
24. Kluin KJ, Gilman S, Markel DS, Koeppe RA, Rosenthal G, Junck L. Speech disorders in olivopontocerebellar atrophy correlate with positron emission tomography findings. Ann Neurol 1988;23:547-554.
25. Bishop DV. T.R.O.G. Test for reception of grammar. Author, University of Manchester, 1983.
26. Catsman-Berrevoets CE, van Harskamp F. Compulsive presleep behavior and apathy due to bilateral thalamic stroke: response to bromocriptine. Neurology 1988;38:647-649.
27. Echiverri HC, Tatum WO, Merens TA, Coker SB. Akinetic mutism: pharmacologic probe of the dopaminergic mesencephalofrontal activating system. Pediatr Neurol 1988; 4:228-230.
28. Ross ED, Steward RM. Akinetic mutism from hypothalamic damage: successful treatment with dopamine agonists. Neurology 1981;31:1435-1439.