



PERGAMON

Neuroscience and Biobehavioral Reviews 24 (2000) 355–364

NEUROSCIENCE AND  
BIOBEHAVIORAL  
REVIEWS

www.elsevier.com/locate/neubiorev

## The amygdala theory of autism

S. Baron-Cohen<sup>a,\*</sup>, H.A. Ring<sup>b</sup>, E.T. Bullmore<sup>a</sup>, S. Wheelwright<sup>a</sup>, C. Ashwin<sup>a</sup>, S.C.R. Williams<sup>c</sup>

<sup>a</sup>*Departments of Experimental Psychology and Psychiatry, University of Cambridge, Downing Street, Cambridge CB2 3EB, UK*

<sup>b</sup>*Academic Department of Psychological Medicine, St. Bartholomew's and the Royal London School of Medicine, Whitechapel, London E1 1BB, UK*

<sup>c</sup>*Neuroimaging Research, Department of Clinical Neuroscience, Institute of Psychiatry, University of London, Denmark Hill, London SE5 8AF, UK*

Received 14 July 1999; accepted 17 December 1999

### Abstract

Brothers (Brothers L. Concepts in Neuroscience 1990;1:27–51) proposed a network of neural regions that comprise the “social brain”, which includes the amygdala. Since the childhood psychiatric condition of autism involves deficits in “social intelligence”, it is plausible that autism may be caused by an amygdala abnormality. In this paper we review the evidence for a social function of the amygdala. This includes reference to the Kluver–Bucy syndrome (which Hetzler and Griffin suggested may serve as an animal model of autism). We then review evidence for an amygdala deficit in people with autism, who are well known to have deficits in social behaviour. This includes a detailed summary of our recent functional magnetic resonance imaging (fMRI) study involving judging from the expressions of another person's eyes what that other person might be thinking or feeling. In this study, patients with autism or AS did not activate the amygdala when making mentalistic inferences from the eyes, whilst people without autism did show amygdala activity. The amygdala is therefore proposed to be one of several neural regions that are abnormal in autism. We conclude that the amygdala theory of autism contains promise and suggest some new lines of research. © 2000 Elsevier Science Ltd. All rights reserved.

*Keywords:* Autism; Kluver–Bucy syndrome; Functional magnetic resonance imaging; Amygdala

Social intelligence is defined here as our ability to interpret others' behaviour in terms of mental states (thoughts, intentions, desires, and beliefs), to interact both in complex social groups and in close relationships, to empathize with others' states of mind, and to predict how others will feel, think, and act. We will use the term social intelligence synonymous with theory of mind [1].<sup>1</sup> Autism is a neuropsychiatric condition that disrupts the development of social intelligence. Studies of autism can therefore allow us to study the neural basis of social intelligence.

The idea that social intelligence might be independent of general intelligence comes from four sources.

- There are individuals who are capable of considerable understanding of the non-social world (e.g. physics, maths, engineering) yet who readily admit to finding the social world confusing [2,3].
- The opposite type of individual also exists: people who have no difficulty interacting with the social world but who find non-social problem-solving confusing [4].

- Certain kinds of brain damage (e.g. to the amygdala) can cause selective impairment in social judgement [5] without any necessary loss to general problem-solving ability. Loss of social judgement can of course co-occur with memory and executive dysfunction [6], but the functional double dissociation between social and non-social intelligence suggests their neural independence.
- Many primatologists now believe that social problem-solving (independently of other factors such as tool-use or other non-social problem-solving) was a key driving force behind the evolution of primate intelligence [7].

A neural basis of social intelligence was first proposed by Brothers [8]. She suggested from both animal lesion studies [9], single cell recording studies [10], and neurological studies (cited above) that social intelligence was a function of three regions: the amygdala, the orbito-frontal cortex (OFC), and the superior temporal sulcus and gyrus (STG). Together, she called these the “social brain”. Elsewhere, we have considered the contributions of the OFC and STG to autism [11,12]. In this paper, we focus on the role of the amygdala in social intelligence, and develop an amygdala theory of autism. The theory proposes that the amygdala is one of several neural regions that are necessarily abnormal in autism.

\* Corresponding author. Fax: + 44-1223-333564.

E-mail address: sb205@cus.cam.ac.uk (S. Baron-Cohen).

<sup>1</sup> We recognise that some social judgments do not require mentalistic inferences; hence emphasising that a specific definition of the term ‘social intelligence’ is being used here.

## 1. The amygdala<sup>2</sup>

The amygdala is a collection of nuclei. It lies beneath the uncus of the temporal lobe at the anterior end of the hippocampal formation and the inferior horn of the lateral ventricle. It develops relatively early in gestation (embryonic day 30–50), but the separate nuclei do not differentiate until postnatal life, suggesting plasticity in the cues to which the amygdala responds [13]. The old view of the amygdala was that it was mainly only interconnected with the hypothalamus, but evidence over the last two decades reveals the amygdala is intricately interconnected with many brain regions, including neocortex, basal forebrain, the “limbic striatum” (nucleus accumbens and ventral pallidum), the neostriatal structures (the caudate nucleus, and the putamen), the hippocampal formation, and the claustrum [14,15]. The amygdala blends in with the periamygdaloid cortex, a part of the uncus. It is also adjacent to the tail of the caudate nucleus. The amygdala does have some connections with the striatum, but the overall pattern of its connections is described next.

### 1.1. Afferents to the amygdala

The amygdala receives a great deal of sensory input in a highly processed form. Single amygdalar cells may respond to somatosensory, visual, auditory, and all types of visceral inputs. The afferents carrying this information reach the amygdala by travelling in the reverse direction along the paths followed by amygdalar efferents. Visceral inputs, particularly olfactory inputs, are especially prominent. Additional visceral information reaches the amygdala indirectly from the hypothalamus, setal area, orbital and insular-cortex, and also by more direct routes; for example, the parabrachial nucleus projects to the amygdala. The temporal and anterior cingulate cortices also project to the amygdala.

### 1.2. Efferents from the amygdala

Fibres leave the amygdala through two major pathways to reach many of the same areas that send efferents to it. The first pathway is the *stria terminalis*, which travels around from the temporal lobe toward the interventricular foramen, together with the caudate nucleus and the thalamostriate (or terminal) vein. The second efferent is the *ventral amygdalofugal pathway*. These fibres pass underneath the lenticular nucleus and spread out to the base of the brain, ending in the septal area and the hypothalamus, in olfactory regions like the anterior olfactory nucleus, the anterior perforated substance, the piriform cortex, and in the orbital and anterior cingulate cortices. Some reach the *ventral striatum*, which includes the area where the putamen and the caudate nucleus (the *nucleus accumbens*) fuse, as well as portions of the striatum. The ventral striatum in turn projects to an

extension of the globus pallidus, the *ventral pallidum*, beneath the anterior commissure. The ventral striatum and pallidum are links in a basal ganglia circuit similar to that involved in motor functions. Many ventral amygdalofugal fibres reach the dorsomedial nucleus of the thalamus. Finally, some amygdalar efferents pass directly to entorhinal cortex and other cortical areas in the temporal lobe and beyond.

## 2. The amygdala nuclei

The amygdala is not a single entity, but comprises a collection of 13 nuclei, located in the medial temporal lobe [16]. For this reason, the amygdala is sometimes called the amygdaloid complex. Traditional classification of the 13 nuclei are into three clusters:

- The *deep* nuclei (lateral, basal, accessory, basal, and paralaminar), which have the greatest interaction with the neocortex and hippocampal formation, and the most connectivity with sensory processing.
- The *superficial* regions (medial, anterior and posterior cortical nuclei), which are more closely associated with olfactory regions and with the hypothalamus. These are thought to play a role in maternal and sexual behaviour.
- *Other* nuclei (central, anterior amygdaloid area, amygdalohippocampal area, and intercalated nuclei). Of these, only the central nucleus has been studied, and it appears to influence the brainstem (e.g. by mediating the cardiovascular and respiratory responses during fear [17]).

Emery, using non-metric multidimensional scaling analysis based on macaque genus brains where the anatomical connections are already defined, suggests slightly different terminology for grouping these 13 nuclei into three clusters [18]. (1) The *basolateral (BL) group* (the lateral, lateral basal, mesial basal, and accessory basal nuclei). The BL group appears to be functionally distinct too, containing neurons responsive to faces and actions of others (Rolls, 1984; [113], 1992; [114]; Leonard et al., 1985; [10]; Brothers and Ring, 1992). These are not found in the next two clusters of amygdala nuclei. (2) The *centromedial (CM) group* (the central, medial, and cortical nuclei, and the periamygdaloid complex). The CM group innervates many of the visceral and autonomic effector regions of the brainstem, such as the parabrachial nuclei (involved in respiratory control) and the dorsal motor nucleus (involved in cardiovascular control). (3) The *peripheral nuclei (PN) group* (cortical transition area, anterior amygdaloid area, and amygdalo-hippocampal area).

Finally, in terms of neurochemistry, the amygdala has the highest density of benzodiazepine/GABA<sub>A</sub> receptors in the brain, and also has a substantial set of opiate receptors. It contains serotonergic, dopaminergic, cholinergic and noradrenergic cell bodies and pathways [19]. For a thorough review of the neuroanatomy of the amygdala, the reader is directed elsewhere [19,20].

<sup>2</sup> Information in this section is based on excellent reviews elsewhere [19,95,96].

### 3. Amygdalar function

As the amygdala has extensive connections with the septal area and hypothalamus and with prefrontal cortex, it influences both drive-related behaviour and the related emotions. In the first of these two roles, the amygdala modulates the hypothalamus. Visceral or somatic activity that can be elicited by stimulating the hypothalamus (such as feeding, or cardiovascular and respiratory changes) can also be elicited by stimulating the amygdala. The role of the amygdala in emotions has also been revealed via electrical studies. When the animal's amygdala is stimulated, the animal typically stops whatever it was doing and becomes attentive. This may be followed by defensiveness, fight, or flight. In humans the most common emotion following amygdalar stimulation is fear, accompanied by its autonomic manifestations (dilation of the pupils, release of adrenalin, and increased heart rate). Conversely, bilateral destruction of the amygdala causes a decrease in aggression, with the result that the animals are described as tame and placid.

### 4. Evidence for the importance of the amygdala in primate social behaviour

There are several important lines of evidence implicating the amygdala in primate social behaviour. Extensive reviews exist elsewhere [9]. Here we summarise the main lines of evidence.

#### 4.1. Lesions of the primate amygdala affect social behaviour

Ibotenic acid lesions of the amygdala affect the social behaviour of adult rhesus macaques [21]. In addition, amygdala-lesioned monkeys become socially isolated. They fail to initiate social interactions, and they fail to respond appropriately to social gestures [9,22]. Kling and colleagues have shown this pattern of effects in rhesus monkeys in semi-natural settings (the Caribbean Regional Primate Center on Cayo Santiago) [23], in caged vervets [24], in free-ranging vervets [25], and in stump-tailed macaques in different sized social groups [26]. The vervet study above showed that when the amygdala-lesioned monkeys were released into the wild they were unresponsive to group members, failed to display appropriate social signals (neither affiliative nor aggressive), they withdrew from other animals, and frequently they were killed. Those who were not killed never re-entered their original social groups. The socio-emotional deficits in amygdala lesions in infant rhesus monkeys produce last into adulthood [27,28].

In one of the earliest studies, Brown and Shafer lesioned the temporal cortex of a rhesus monkey and documented significant social and emotional deficits as a result [29]. This result was extended by Kluver and Bucy who showed that large lesions of the anterior temporal lobe (including amygdala, hippocampal formation, and temporal cortex) produced a syndrome which included the following symptoms: a

tendency to over-react to all objects, hypoemotionality and loss of fear, hypersexuality<sup>3</sup> (excessive masturbation, copulation with any object, and fellatio with both same sex and opposite sex monkeys), hyperorality (a tendency to investigate objects with their mouths, not their hands, even if the object was inedible), and in some (but not all) cases, an inability to recognize objects (visual agnosia) [30]. They called this new syndrome "psychic blindness"<sup>4</sup> because the monkeys would approach animate and inanimate objects indiscriminately.<sup>5</sup> Most striking was the loss of fear towards the experimenters, and a blunting of aggression.

Subsequent work showed that the amygdala was found to be responsible for the emotional, oral, and sexual deficits [31,32]; the temporal cortex was responsible for the visual deficits [31,33]; and the dual lesions produced the combined and full syndrome [34]. Aggleton and Passingham [35] made selective radio frequency lesions of the whole amygdala, the basal and lateral nuclei, the lateral nucleus alone, the dorsal nuclei, and the white matter that borders the amygdala laterally and dorsally (the temporal stem). Their results showed that only lesions of the whole amygdala caused the complete Kluver–Bucy syndrome. Note that the sexual aberrations are not always replicated in juvenile monkeys with Kluver–Bucy syndrome [33].

Bachevalier lesioned either the medial temporal lobe (including the amygdala, periamygdaloid cortex, hippocampus, entorhinal and perirhinal cortices), or the hippocampal formation and amygdala separately [36,37]. The lesioned animal infants were raised and paired with an age-matched control animal. At two months, the infants with medial temporal lobe lesions were more passive, displayed increased temper tantrums, and initiated fewer social contacts. At six months they interacted very little with the control animal, and actively withdrew from all approaches by the normal animals. The animals with medial temporal lobe lesions also displayed emotionally expressionless faces and showed more self-directed behaviour and motor stereotypies. Such abnormalities were still evident in adulthood. Amygdala lesions alone produced a similar pattern of social abnormalities, but to a lesser extent.

Rosvold et al. showed that amygdala lesions in monkeys had a direct effect on the animal's social status: social hierarchies were disrupted, this being due to the most dominant animal falling in dominance following the amygdala lesion

<sup>3</sup> Emery and Amaral (in press) [115], note that the projection from the amygdala to the hypothalamus may be involved in the initiation of penile erection and ejaculation, as electrical stimulation of the amygdala can cause these (Robinson and Mishkin, 1966; [116]; 1968; [117]).

<sup>4</sup> "Psychic blindness" may approximate as a non-human animal equivalent of "mindblindness" [97].

<sup>5</sup> It is noteworthy for the amygdala theory of autism outlined later in this paper that the original description of young children with autism referred to this lack of a differential response to people (animate objects) and things (inanimate objects) [98]. The similarity between this aspect of the behaviour of the monkeys with Kluver–Bucy syndrome and children with autism may reflect a common aetiological factor: amygdala abnormality.

[38]. Lesions in the amygdala of monkey mothers lead to the mothers showing a reduction in maternal behaviours towards her infant (suckling, cuddling, or protecting them), with the result that amygdala-lesioned mother monkeys are more likely to physically abuse or neglect their infants [39–43]. Note that amygdala lesions in infant monkeys do not disrupt the drive for attachment [44] but they do have major effects on initiating and responding to peer social interaction [37]. The data from non-human primates is largely consistent with the data from human lesion studies [45–47].

#### 4.2. Amygdala volume and group size

There is a significant correlation between amygdala volume and social group size (a positive correlation with the BL group, and a negative correlation with the CM group) [18]. This correlation remains significant even after removing the effects of overall brain size and the rest of the amygdala, as well as the effect of body size. This was computed for 44 primate species, excluding humans. In the Emery et al. study, group size is taken as a proxy measure of social complexity, and therefore an indicator of the likely evolutionary selection pressure on ‘social intelligence’. (It is acknowledged that this is an imperfect proxy measure, since species such as ants, termites, and bees live in large social groups but do not have the social intelligence of any primate). A similar correlation has been reported between social group size and neocortex size in primates [48]. On the basis of the correlation with the amygdala and social group size, Emery and Perrett emphasize the BL group as the cluster of amygdala nuclei with the clearest role in social cognition, relative to the other two amygdala clusters of nuclei (Emery and Perrett, in press). This is also based on the connections between the BL group and superior temporal sulcus and gyros, orbito-frontal and medial frontal cortex (STG, OFC, and MFC), which have all been demonstrated to play a role in social cognition.<sup>6,7</sup>

<sup>6</sup> In the anterior superior temporal polysensory area, STPa [99] in the macaque monkey, there are cells which are relevant to understanding others’ actions (Emery and Perrett, in press). (a) One type of cell encodes the visual appearance of the face and body [100–102]. These include cells responsive to certain facial expressions (anger, fear). (b) A second type of cell codes facial and body movements but not still images of these [103,104]. (c) A third type of cell codes facial and bodily movements as goal directed actions—for example, it responds to hands reaching for an object, but not to a hand movement alone). This cell type is found throughout the STG, and particularly frequently in area TEa [105,106]. Finally, (d) there is a cell type which codes any movement which is not a predictable consequence of the monkey’s own actions [107,108].

<sup>7</sup> The orbito-frontal and medial frontal cortex are also important for social intelligence, and are connected to the amygdala. For example, damage to the OFC impairs judgement of what is socially appropriate [109], and recent PET and SPECT studies of “theory of mind” (or the ability to impute mental states) also implicate areas of prefrontal cortex, specifically the medial frontal cortex (MFC) [110,111] and the OFC [12]. We consider the OFC in our earlier papers [11,112], to which the reader is referred.

#### 4.3. Neuroimaging studies in humans

The human amygdala is activated in humans when decoding signals of social importance, such as gaze, expression–recognition (especially of fearful faces), and body movements) [49–54].

#### 4.4. The amygdala, opiate system, and social grooming

The amygdala plays a major role in affiliative behaviours in primates, via grooming. Grooming when it is self-directed (autogrooming) is probably mainly aimed at cleaning the body surface, but when it is social (allogrooming) it is thought to be primarily related to the formation and maintenance of social relationships and coalitions [55,56]. Allogrooming reduces tension [57] via a decrease in heart rate, which is thought to be controlled by the central nucleus of the amygdala [58]. One mechanism for this is via the opiate system, since blocking opiate receptors with the opioid antagonist, naltrexone, increases allogrooming in talapoin monkeys [59–61]. Following social contact a measurable increase in opioid levels is also seen [62]. The link between opioid level, allogrooming/affiliative behaviour, and the amygdala is postulated because the amygdala contains a large number of opiate receptors [63].

Since this paper focuses primarily on the amygdala, we do not discuss the other postulated regions in the social brain, the superior temporal gyrus<sup>6</sup> or the orbito and medial–frontal cortex.<sup>7</sup>

### 5. Evidence for an amygdala abnormality in autism

We turn now to consider six lines of evidence for an amygdala deficit in autism.

#### 5.1. Post-mortem evidence

A neuroanatomical study of autism at post-mortem found microscopic pathology (in the form of increased cell density) in the amygdala, in the presence of normal amygdala volume [64,65].

#### 5.2. An animal model of autism

The only animal model of autism involves ablation of the amygdala (in rhesus monkeys) [36]. (See above). There are obviously limits to any animal model of autism, given that the syndrome involves deficits in higher-order cognition, but Bachevalier makes the case that the effects of amygdala lesions in monkeys resemble some of the symptoms of autism. In particular, the Kluver–Bucy syndrome seems a fairly good animal model of autism [66].

#### 5.3. Similarities between autism and patients following amygdalotomy

Patients with amygdala lesions show impairments in

social judgement [45,47] which have been likened to “acquired autism” [67]. The age of onset of deficits in acquired vs idiopathic cases is likely to mean that the two syndromes also differ in many ways, too. Similarly, patients with autism tend to show a similar pattern of deficits to those seen in patients with amygdala lesions [68].

#### 5.4. The effects of temporal lobe tubers

In cases of tuberous sclerosis, autistic comorbidity is determined by hamartomata in the temporal lobe [69].<sup>8</sup>

#### 5.5. Structural neuroimaging

A recent structural magnetic resonance imaging study of autism reported reduced amygdala volume [70].

#### 5.6. Functional neuroimaging

Using single photon emission computed tomography (SPECT), patients with autism spectrum conditions show significant reductions in temporal lobe blood flow. This is not simply an effect of temporal lobe epilepsy [71]. In our recent functional magnetic resonance imaging (fMRI) study, we found that adults with HFA or AS showed significantly less amygdala activation during a mentalizing task (Judging the mind in the Eyes task), compared to normal [49]. Because it constitutes the first direct *in vivo* evidence for a functional amygdala deficit in autism, we describe this study in detail next.

### 6. fMRI Study of high functioning autism/asperger syndrome

The following is a summary of the above fMRI study [49]. Six subjects with autism (4m, 2f) were matched for mean age, handedness, IQ, socioeconomic status, and educational level, with 12 subjects in the normal group (6m, 6f). IQ was assessed with the full Wechsler Adult Intelligence Scale (WAIS-R). Subjects were only included if their IQ was in the normal range (i.e. above 85 both in terms of full-scale IQ, and in terms of performance and verbal IQ). Individuals in the clinical group all had a diagnosis of autism or Asperger Syndrome, using established criteria [72,73].

In the fMRI scanner, a blocked periodic ABA design was employed. Each epoch (A or B) was presented for 30 s, and there were five cycles of AB alternation in total. Images were acquired from each subject during visual presentation of two tasks, both of which involved deriving socially relevant information from facial stimuli. This periodically designed (ABA) experiment was expected to induce

periodic MR signal change with signal maximum during task A in brain regions relatively specialized for gender recognition from facial stimuli; and periodic MR signal change with signal maximum during task B in brain regions relatively specialized for mental state recognition from facial stimuli. The response involved a forced choice between the two words offered (pressing one of two buttons with the right hand to select the right or left word). Correct words were counterbalanced to left and right side.

*Task A.* Subjects were visually presented with a series of photographs of eyes and asked to indicate by right handed button press whether each stimulus was a man or a woman. In this first task (A: gender recognition), instructions to subjects were to decide for each stimulus which of two simultaneously presented words (“male” or “female”) best described the face. Each stimulus was presented for 5 s and was followed by a 0.75 s interval in which the screen was blank. Stimuli were drawn from 30 faces of women or men. Stimuli were presented 3.5 m from the subject, subtending visual angles of 10° horizontally and 8° vertically.

*Task B.* Subjects were presented with exactly the same stimuli but were asked to indicate by button press which of two simultaneously presented words best described the mental state of the photographed person. Thus, the key difference between the two tasks was the type of judgement the subject had to make when viewing the eyes. Subjects were presented with an example of the stimuli before scanning. For this second task (B: theory of mind), instructions to subjects was to decide for each stimulus which of two simultaneously presented words best described what the person in the photograph was feeling or thinking. Task B is an “advanced” theory of mind test, in that it is used with adults.

Adults with high-functioning autism or AS, with intelligence in the normal range, show deficits on this task [74], as do parents of children with autism/AS [75]. Children with William’s Syndrome are not impaired on this test, despite their general retardation [76]. Examples of the eyes used in the experimental condition, together with the forced choice words that appeared underneath each face, are shown in Fig. 1.

Functional MRI data were analysed in two stages: first, generic brain activation maps were constructed separately for the control and autism groups. These maps identified voxels demonstrating significant power of periodic signal change over all subjects in each group; they also represented differences between generically activated voxels in terms of phase of response to the experimental input function. Thus it was possible to determine which voxels were activated in each group by each of the two tasks. Second, we used ANOVA to identify voxels that demonstrated a significant difference between groups in mean power of response to each task.

Fig. 2 shows the functional system activated by presentation of the theory of mind task in the control and autism groups. This system can be anatomically subdivided into two main components: (i) a set of *fronto-temporal*

<sup>8</sup> We emphasize the amygdala theory of autism, though some of the lines of evidence cited here implicate temporal lobe structures, which include the amygdala but also include other adjacent mesiotemporal areas. It remains for future work to establish the specificity of an amygdala deficit in autism.




Fig. 1. Examples of the stimuli used. During Task B photographs of eyes were presented with a choice of mental state words (examples as shown); during Task A the eyes were presented with a choice of the words “male” and “female”. (Top example: correct word in Task B = Concerned; correct word in Task A = Female. Both example: correct word in Task B = Sympathetic; correct word in Task A = Female).

neocortical regions, comprising left dorsolateral prefrontal cortex (DLPFC) approximately Brodmann area (BA) 44, 45, 46; the left medial frontal cortex MFC (BA 9); supplementary motor area (SMA) (medial BA 6); and bilateral temporo-parietal regions, including middle and superior temporal, angular and supramarginal gyri (BA 21, 22, 39, and 40); and (ii) a number of *non-neocortical* areas, including the left amygdala, the left hippocampal gyrus (BA 27 and 30), bilateral insulae, and left striatum.

The autism group activated the frontal components less extensively than the control group; and did not activate the amygdala at all. As shown in Table 1, the control group demonstrated significantly greater power of response in the left amygdala, right insula, and left inferior frontal gyrus. The autism group demonstrated significantly greater power of response in bilateral superior temporal gyrus (STG).

Regarding the left amygdala, this area may be critically involved in identifying mental state/emotional information from complex visual stimuli such as the eye region. This laterality effect is consistent with previous studies: the left amygdala appears to be specifically activated in emotion processing [52,77] (but see [78,79]). The autism group appears not to perform the task using the amygdala, but instead place a greater processing load on temporal lobe structures, specialized for verbally labelling complex visual stimuli and processing faces and eyes. This may arise as a compensation for an amygdala abnormality.

This study suggests that mental state concepts are processed in the amygdala, both when the task involves inferring mental states from eyes, or other animate actions [50]. The fMRI study provides strong evidence of the role of the amygdala in normal social intelligence, and abnormality of the amygdala in autism. Although some structural

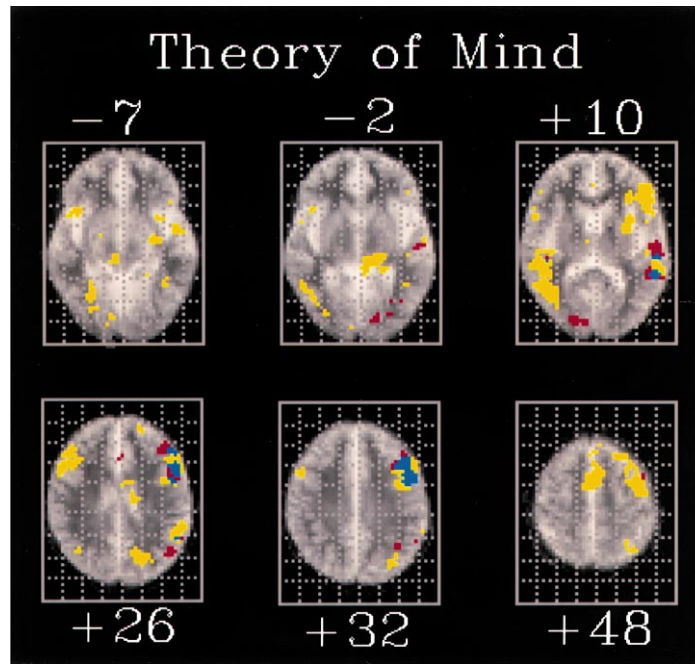


Fig. 2. Generic brain activation maps separately computed from the control and autistic group data are superimposed in standard space. Only those voxels with maximum signal during the theory of mind task are shown. Voxel-wise probability of Type I error  $\alpha = 0.008$  for both maps. Voxels activated in the control group only are coloured yellow; voxels activated in the autism group only are coloured red; voxels activated coincidentally in both groups are coloured blue. The right side of each map represents the left side of the brain. The z coordinates (mm) of each slice relative to the intercommissural line in the standard space [94] is shown above or below each slice. At  $-7$  mm, the control group activated regions including bilateral insulae and left amygdala; at  $-2$  mm, the main focus of activation in the control group is located in left parahippocampal gyrus; at  $+10$  mm, the control group demonstrates activation of bilateral superior temporal gyrus (STG) and left prefrontal cortex, while the autism group demonstrates less extensive activation of predominantly left sided STG; at  $+26$  and  $+32$  mm, both groups activate left prefrontal cortex.

imaging studies of the amygdala in autism suggests this is normal [80,81], others have documented anomalies [70] and the fMRI study described above suggests functional anomalies exist.

## 7. Other brain areas that might be abnormal in autism

Whilst this paper highlights the necessary role on amygdala abnormality might play in autism, we do not suggest that this is the only abnormal neural region. For example, the case has been made for anomalous functioning in the cerebellum [82], hippocampal formation [83], medial frontal cortex [84], and fronto-limbic connections [85] in autism. Reduced neuron size and increased cell-packing

density has also been found in the limbic system, specifically the hippocampus, subiculum, entorhinal cortex, amygdala, mammillary bodies, anterior cingulate, and septum in autism [64,86–89]. A full review of neuroimaging of autism may be found elsewhere [80]. Here, we instead follow a line of argument begun by other authors emphasising an amygdala theory of autism [37,66,86]. This is consistent with studies showing temporal lobe and limbic epilepsy in a proportion of children with autism [90]; for an excellent review see Ref. [37].

## 8. Future work

The literature reviewed in this paper hints at the validity

Table 1  
Main brain regions differentially activated by theory of mind task between control (C) and autism (A) groups. BA = Brodmann area

Cerebral region	BA	Side	N (voxels)	x	y	z	Difference	P
Superior temporal gyrus or Wernicke's area	22	L	12	-55	-28	15	A > C	0.004
Superior temporal gyrus	22	R	8	40	-28	15	A > C	0.002
Inferior frontal gyrus or Broca's area	44/45	L	5	-46	22	9	C > A	0.001
Insula		R	5	40	11	-7	C > A	0.001
Amygdala		L	4	-23	-11	-7	C > A	0.001

of an amygdala theory of autism, but future studies will be needed to test this more extensively. For example, it will be important to test if the amygdala in autism can be activated to normal levels using other cognitive tasks, or if the deficit associated with the Eyes Task extends to other tests of social intelligence.

Secondly, it is known that the amygdala plays a role in the recognition of fear [45,46,91]. Related to this, the amygdala is implicated in the formation of conditioned fear responses to auditory stimuli [47,92]. If there is an amygdala deficit in autism this might be expected to lead to abnormal fear responses in such children (either showing too little or too much fear, compared to non-autistic controls). Studies of fear in autism might be an indirect method to test predictions from the amygdala theory. Finally, future research will need to specify in greater detail, which of the 13 nuclei in the amygdala are intact in autism, and which are impaired.

### Acknowledgements

This work was funded by a grant to SBC, HR, and SCW from the Wellcome Trust, and by a grant to the first author from the Gatsby Foundation. EB is also supported by the Wellcome Trust. We are grateful to Barry Everitt for comments on the first draft of this paper. We have also benefited from review papers by Nathan Emery and colleagues (Emery and Perrett, in press; [93]).

### References

- [1] Wellman H. Children's theories of mind. Bradford: MIT Press, 1990.
- [2] Baron-Cohen S, Wheelwright S, Stone V, Rutherford M. A mathematician, a physicist, and a computer scientist with Asperger Syndrome: performance on folk psychology and folk physics test. *Neurocase* 2000 (in press).
- [3] Sacks O. *An anthropologist on Mars*, 1994.
- [4] Karmiloff-Smith A, Grant J, Bellugi U, Baron-Cohen S. Is there a social module? Language, face-processing and theory of mind in William's Syndrome and autism. *Journal of Cognitive Neuroscience* 1995;7:196–208.
- [5] Damasio A, Tranel D, Damasio H. Individuals with sociopathic behaviour caused by frontal lobe damage fail to respond autonomically to socially charged stimuli. *Behavioural Brain Research* 1990;14:81–94.
- [6] Tranel D, Hyman BT. Neuropsychological correlates of bilateral amygdala damage. *Archives on Neurology* 1990;47:349–55.
- [7] Whiten A. *Natural theories of mind*. Oxford: Blackwell (Basil), 1991.
- [8] Brothers L. The social brain: a project for integrating primate behaviour and neurophysiology in a new domain. *Concepts in Neuroscience* 1990;1:27–51.
- [9] Kling A, Brothers L. The amygdala and social behaviour. In: Aggleton J, editor. *Neurobiological aspects of emotion, memory, and mental dysfunction*. New York: Wiley, 1992.
- [10] Brothers L, Ring B, Kling A. Responses of neurons in the macaque amygdala to complex social stimuli. *Behavioural Brain Research* 1990;41:199–213.
- [11] Baron-Cohen S, Ring H. A model of the mindreading system: neuropsychological and neurobiological perspectives. In: Mitchell P, Lewis C, editors. *Origins of an understanding of mind*. Hillsdale, NJ: Lawrence Erlbaum, 1994.
- [12] Baron-Cohen S, Ring H, Moriarty J, Shmiltz P, Costa D, Ell P. Recognition of mental state terms: a clinical study of autism, and a functional neuroimaging study of normal adults. *British Journal of Psychiatry* 1994;165:640–9.
- [13] Kordower JH, Piecinski P, Rakic P. Neurogenesis of the amygdaloid nuclear complex in the rhesus monkey. *Developmental Brain Research* 1992;68:9–15.
- [14] Russchen FT, Amaral DG, Price JL. The afferent connections of the substantia innominata in the monkey, *Macaca fascicularis*. *Journal of Comparative Neurology* 1985;242:1–27.
- [15] Russchen FT, Bakst I, Amaral DG, Price JL. The amygdalostriatal projections in the monkey. an anterograde tracing study. *Brain Research* 1985;329:241257.
- [16] Amaral DG, Price JL, Pitkanen A, Carmichael ST. Anatomical organisation of the primate amygdaloid complex. In: Aggleton JP, editor. *The amygdala: neurobiological aspects of emotion, memory and mental dysfunction*. New York: Wiley, 1991. p. 1–66.
- [17] LeDoux JE. *The emotional brain: the mysterious underpinnings of emotional life*. New York: Simon and Schuster, 1996.
- [18] Emery NJ, Lorincz EN, Perrett DI, Oram MW, Baker CI. Gaze following and joint attention in rhesus monkeys (*Macaca mulatta*). *Journal of Comparative Psychology* 1997;111:1–8.
- [19] Nolte J. *The human brain: an introduction to its functional anatomy*. 3rd ed. St. Louis: Mosby, Year Book, 1993.
- [20] Aggleton JP, editor. *The amygdala: neurobiological aspects of emotion, memory, and mental dysfunction*. New York: Wiley, 1992.
- [21] Emery NJ, Machado CJ, Capitanio JP, Mendoza SP, Mason WA, Amaral DG. The role of the amygdala in dyadic social interaction and the stress response in monkeys. *Society for Neuroscience Abstracts* 1998;312:4.
- [22] Kling A, Steklis HD. A neural substrate for affiliative behaviour in nonhuman primates. *Brain, Behaviour and Evolution* 1976;13:216–38.
- [23] Dicks D, Myers RE, Kling A. Uncus and amygdala lesions: effects on social behaviour in the free ranging rhesus monkey. *Science* 1969;165:69–71.
- [24] Kling A. Effects of amygdectomy and testosterone on sexual behaviour of male juvenile macaques. *Journal of Comparative and Physiological Psychology* 1968;65:466–71.
- [25] Kling A, Lancaster J, Bentone J. Amygdectomy in the free ranging vervet. *Journal of Psychiatric Research* 1970;7:191–9.
- [26] Kling A, Cornell R. Amygdectomy and social behaviour in the caged stump-tailed macaque. *Folia Primatologia* 1971;14:91–103.
- [27] Thompson CI, Bergland RM, Towfighi JT. Social and nonsocial behaviours of adult rhesus monkeys after amygdectomy in infancy or adulthood. *Journal of Comparative and Physiological Psychology* 1977;91:533–48.
- [28] Thompson CI, Towfighi JT. Social behaviour of juvenile rhesus monkey after amygdectomy. *Physiology and behaviour* 1976;17:831–6.
- [29] Brown S, Shafer EA. An investigation into the functions of the occipital and temporal lobes of the monkey's brain. *Philosophical Transactions of the Royal Society of London: Biological Sciences* 1988;179:303–27.
- [30] Kluver H, Bucy P. Preliminary analysis of function of the temporal lobe in monkeys. *Archives of Neurology* 1939;42:979–1000.
- [31] Horel JA, Keating EG, Misantone LJ. Partial Kluver–Bucy syndrome produced by destroying temporal neocortex or amygdala. *Brain Research* 1975;94:347–59.
- [32] Weiskrantz L. Behavioural changes associated with ablation of the amygdaloid complex in monkeys. *Journal of Comparative Physiology and Psychology* 1956;4:381–91.
- [33] Akert K, Gruesen RA, Woolsey CN, Meyer DR. Kluver–Bucy syndrome in monkeys with neocortical ablations of the temporal lobe. *Brain* 1961;84:480–97.



- [34] Aggleton JP, Mishkin M. Visual impairments in macaques following inferior temporal lesions are exacerbated selectively by additional damage to superior temporal sulcus. *Behaviours Brain Research* 1990;39:262–74.
- [35] Aggleton JP, Passingham RE. Syndrome produced by lesions of the amygdala in monkeys (*Macaca mulatta*). *Journal of Comparative and Physiological Psychology* 1981;95:961–77.
- [36] Bachevalier J. An animal model for childhood autism: memory loss and socioemotional disturbances following neonatal damage to the limbic system in monkeys. In: Tamminga C, Schulz S, editors. *Schizophrenia research, Advances in Neuropsychiatry and Psychopharmacology*, vol. 1. New York: Raven Press, 1991.
- [37] Bachevalier J. Medial temporal lobe structures and autism: a review of clinical and experimental findings. *Neuropsychologia* 1994;32:627–48.
- [38] Rosvold HE, Mirsky AF, Pribram KH. Influence of amygdectomy on social behaviour in monkeys. *Journal of Comparative and Physiological Psychology* 1954;47:173–8.
- [39] Bucher K, Myers R, Southwick C. Anterior temporal cortex and maternal behaviour in monkey. *Neurology* 1970;20:415.
- [40] Franzen EA, Myers RE. Neural control of social behaviour: prefrontal and anterior temporal cortex. *Neuropsychologia* 1973;11:141–57.
- [41] Kling A. Effects of amygdectomy on socio-affective behaviour in non-human primates. In: Eleftheriou BE, editor. *Neurobiology of the amygdala*. New York: Plenum Press, 1972. p. 511–36.
- [42] Masserman JH, Levitt M, McAvoy T, Kling A, Pechtel C. The amygdalae and behaviour. *American Journal of Psychiatry* 1958;115:14–17.
- [43] Myers RE, Swett C, Miller M. Loss of social group affinity following prefrontal lesions in free-ranging macaques. *Brain Research* 1973;64:257–69.
- [44] Stecklis HD, Kling A. Neurobiology of affiliative behaviour in nonhuman primates. In: Reite, Field T, editors. *The psychobiology of attachment and separation*. New York: Academic Press, 1985. p. 93–134.
- [45] Adolphs R, Tranel D, Damasio H, Damasio A. Impaired recognition of emotion in facial expressions following bilateral damage to the human amygdala. *Nature* 1994;372:669–72.
- [46] Scott S, Young A, Calder A, Hellowell D, Aggleton J, Johnson M. Impaired auditory recognition of fear and anger following bilateral amygdala lesions. *Nature* 1997;385:254–7.
- [47] Young A, Hellowell D, De Wal C, Johnson M. Facial expression processing after amygdectomy. *Neuropsychologia* 1996;34:31–39.
- [48] Joffe TH, Dunbar RI. Visual and socio-cognitive information processing in primate brain evolution. *Proceedings of the Royal Society of London B: Biological Sciences* 1997;264:1303–7.
- [49] Baron-Cohen S, Ring H, Wheelwright S, Bullmore E, Brammer M, Simmons A, Williams S. Social intelligence in the normal and autistic brain: an fMRI study. *European Journal of Neuroscience* 1999;11:1891–8.
- [50] Bonda E, Petrides M, Ostry D, Evans A. Specific involvement of human parietal systems and the amygdala in the perception of biological motion. *Journal of Neuroscience* 1996;15:3737–44.
- [51] Kawashima R, Sugiura M, Kato T, Nakamura A, Hatano K, Ito K, Fukuda H, Kojima S, Nakamura K. The human amygdala plays an important role in gaze monitoring. *Brain* 1999;122:779–83.
- [52] Morris J, Frith C, Perrett D, Rowland D, Young A, Calder A, Dolan R. A differential neural response in the human amygdala to fearful and happy facial expressions. *Nature* 1996;383:812–5.
- [53] Whalen PJ, Rauch SL, Etcoff NL, McInerney SC, Lee MB, Jenike MA. Masked presentations of emotional facial expressions modulate amygdala activity without explicit knowledge. *The Journal of Neuroscience* 1998;18:411–8.
- [54] Wicker B, Michel F, Henaff M, Decety J. Brain regions involved in the perception of gaze: a PET study. *Neuroimage* 1998;8:221–7.
- [55] Dunbar RIM. Functional significance of social grooming in primates. *Folia Primatologia* 1991;57:121–31.
- [56] Tomasello M, Call J. *Primate cognition*. New York: Oxford University Press, 1997.
- [57] Schino G, Scucchi S, Maestriepieri D, Turillazzi PG. Allogrooming as a tension–reduction mechanism: a behavioural approach. *American Journal of Primatology* 1988;16:43–50.
- [58] Reis DJ, Oliphant MC. Bradycardia and tachycardia following electrical stimulation of the amygdaloid region in monkey. *Journal of Neurophysiology* 1964;27:893–912.
- [59] Fabre-Nys C, Meller RE, Keverne EB. Opiate antagonists stimulate affiliative behaviour in monkeys. *Pharmacology, Biochemistry and Behaviour* 1982;16:653–9.
- [60] Martel FL, Nevison CM, Simpson MJA, Keverne EB. Effects of opioid receptor blockade on the social behaviour of rhesus monkeys living in large family groups. *Developmental Psychobiology* 1995;28:71–84.
- [61] Meller RE, Keverne EB, Herbert J. Behavioural and endocrine effects of naltrexone in male talapoin monkeys. *Pharmacology, Biochemistry and Behaviour* 1980;13:663–72.
- [62] Keverne EB, Martensz ND, Tuite B. Beta-endorphin concentrations in cerebrospinal fluid of monkeys are influenced by grooming relationships. *Psychoneuroendocrinology* 1989;14:155–61.
- [63] LaMotte CC, Snowman A, Pert CB, Snyder SH. Opiate receptor binding in rhesus monkey brain: associating with limbic structures. *Brain Research* 1978;155:374–9.
- [64] Bauman M, Kemper T. *The Neurobiology of Autism*. Baltimore: Johns Hopkins, 1994.
- [65] Rapin I, Katzman R. Neurobiology of Autism. *Annals of Neurology* 1998;43:7–14.
- [66] Hetzler B, Griffin J. Infantile autism and the temporal lobe of the brain. *Journal of Autism and Developmental Disorders* 1981;9:153–7.
- [67] Stone V. The role of the frontal lobes and the amygdala in theory of mind. In: Baron-Cohen S, Tager Flusberg H, Cohen D, editors. *Understanding other minds: perspectives from autism and developmental cognitive neuroscience*. Oxford: Oxford University Press, 2000.
- [68] Adolphs R, Sears L, Piven J. Submitted for publication.
- [69] Bolton P, Griffiths P. Association of tuberous sclerosis of temporal lobes with autism and atypical autism. *Lancet* 1997;349:392–5.
- [70] Abell F, Krams M, Ashburner J, Passingham R, Friston K, Frackowiak R, Happe F, Frith C, Frith U. The neuroanatomy of autism: a voxel-based whole brain analysis of structural scans. *Cognitive Neuroscience* 1999;10:1647–51.
- [71] Gillberg I, Bjure J, Uverbrant P, Vestergren E, Gillberg C. SPECT in 31 children and adolescents with autism and autistic like syndromes. *European Child and Adolescent Psychiatry* 1993;2:50–59.
- [72] APA. *DSM-IV Diagnostic and statistical manual of mental disorders*. 4th ed. Washington, DC: American Psychiatric Association, 1994.
- [73] ICD-10. *International classification of diseases*. 10th ed., Geneva, Switzerland: World Health Organisation.
- [74] Baron-Cohen S, Jolliffe T, Mortimore C, Robertson M. Another advanced test of theory of mind: evidence from very high functioning adults with autism or Asperger Syndrome. *Journal of Child Psychology and Psychiatry* 1997;38:813–22.
- [75] Baron-Cohen S, Hammer J. Parents of children with Asperger Syndrome: what is the cognitive phenotype? *Journal of Cognitive Neuroscience* 1997;9:548–54.
- [76] Tager-Flusberg H, Boshart J, Baron-Cohen S. Reading the windows of the soul: evidence of domain specificity sparing in Williams syndrome. *Journal of Cognitive Neuroscience* 1998;10:631–9.
- [77] Ketter T, Andreason P, George M, Lee C, Gill D, Parekh P, Willis M, Herscovitch P, Post R. Anterior paralimbic mediation of procaine induced emotional and psychosensory experience. *Archives of General Psychiatry* 1996;53:59–69.

- [78] Breiter HC, Etcoff NL, Whalem PJ, Kennedy WA, Rauch SL, Buckner RL, Strauss MM, Hyman SE, Rosen BR. Response and habituation of the human amygdala during visual processing of facial expression. *Neuron* 1996;17:875–87.
- [79] Phillips M, Young A, Senior C, Brammer M, Andrew C, Calder A, Bullmore E, Perrett D, Rowland D, Williams S, Gray J, David A. A specific neural substrate for perceiving facial expressions of disgust. *Nature* 1997;389:495–8.
- [80] Filipek PA. Neuroimaging in the developmental disorders: the state of the science. *Journal of Child Psychology and Psychiatry* 1999;40:113–28.
- [81] Nowell MA, Hackney DB, Muraki AS, Coleman M. Varied MR appearance of autism: fifty-three pediatric patients having the full autistic syndrome. *Magnetic Resonance Imaging* 1990;8:811–6.
- [82] Courchesne E, Townsend J, Akshoomof NA, Saitoh O, Yeung-Courchesne R, Lincoln AJ, James HE, Haas RH, Schreibman L, Lau L. Impairment in shifting attention in autistic and cerebellar patients. *Behavioural Neuroscience* 1994;108:848–65.
- [83] De Long GR. Autism, amnesia, hippocampus, and learning. *Neuroscience Behaviour Review* 1992;16:63–70.
- [84] Happe F, Ehlers S, Fletcher P, Frith U, Johansson M, Gillberg C, Dolan R, Frackowiak R, Frith C. Theory of mind in the brain. Evidence from a PET scan study of Asperger Syndrome. *NeuroReport* 1996;8:197–201.
- [85] Bishop DVM. Annotation: autism, executive functions, and theory of mind: a neuropsychological perspective. *Journal of Child Psychology and Psychiatry* 1993;54:279–93.
- [86] Bauman M, Kemper T. Limbic and cerebellar abnormalities: consistent findings in infantile autism. *Journal of Neuropathology and Experimental Neurology* 1988;47:369.
- [87] Bauman M, Kempner T. Histoanatomic observation of the brain in early infantile autism. *Neurology* 1985;35:866–74.
- [88] Bauman ML, Kempner TL. Developmental cerebellar abnormalities: a consistent finding in early infantile autism. *Neurology* 1986;36:190.
- [89] Raymond G, Bauman M, Kemper T. Hippocampus in autism: a Golgi analysis. *Acta Neuropathology* 1996;91:117–9.
- [90] Payton JB, Minshew NJ. Early appearance of partial complex seizures in children with infantile autism. *Annals of Neurology* 1987;22:408.
- [91] Calder AJ, Young AW, Rowland D, Perrett DI, Hodges JR, Etcoff NL. Facial emotion recognition after bilateral amygdala damage: differentially severe impairment of fear. *Cognitive Neuropsychology* 1996;13:699–745.
- [92] LeDoux JE. Emotion: clues from the brain. *Annual Review of Psychology* 1995;46:209–35.
- [93] Emery NJ, Perrett DI. How can studies of the monkey brain help us understand 'theory of mind' and autism in humans? In: Baron-Cohen S, Cohen D, Tager-Flusberg H, editors. *Understanding other minds 2: perspectives from autism and cognitive neuroscience*, Oxford: Oxford University Press, 2000 (in press).
- [94] Talairach J, Tournoux P. *Coplanar stereotaxic atlas of the human brain*. New York: Thieme Medical, 1988.
- [95] Adolphs R. Social cognition and the human brain. *Trends in Cognitive Sciences* 1999;3:469–79.
- [96] Holland P, Gallagher M. Amygdala circuitry in attentional and representational processes. *Trends in Cognitive Sciences* 1999;3:65–73.
- [97] Baron-Cohen S. *Mindblindness: an essay on autism and theory of mind*. Boston: MIT Press/Bradford Books, 1995.
- [98] Kanner L. Autistic disturbance of affective contact. *Nervous Child* 1943;2:217–50.
- [99] Felleman DJ, Van Essen DC. Distributed hierarchical processing in the primate cerebral cortex. *Cerebral Cortex* 1991;1:1–47.
- [100] Gross C, Rocha-Miranda C, Bender D. Visual properties of neurons in the inferotemporal cortex of the macaque. *Journal of Neurophysiology* 1972;35:96–111.
- [101] Perrett D, Hietanen M, Oram W, Benson P. Organization and function of cells responsive to faces in the temporal cortex. In: Bruce V, Cowey A, Ellis A, Perrett D, editors. *Processing the facial image*, Philosophical Transactions of the Royal Society of London, vol. B335. Oxford: Oxford University Press, 1992. pp. 1–128.
- [102] Wachsmuth E, Oram MW, Perrett DI. Recognition of objects and their components parts: responses of single units in the temporal cortex of the macaque. *Cerebral Cortex* 1994;5:509–22.
- [103] Oram MW, Perrett DI. Responses of anterior superior temporal polysensory (STPa) neurons to biological motion stimuli. *Journal of Cognitive Neuroscience* 1994;6:99–116.
- [104] Oram MW, Perrett DI, editors. *Neural processing of biological motion in the macaque temporal cortex*, vol. 2054. 1994.
- [105] Perrett DI, Harries MH, Bevan R, Thomas S, Benson PJ, Mistlin AJ, Chitty AJ, Hietanen JK, Ortega JE. Frameworks of analysis for the neural representation of animate objects and actions. *Journal of Experimental Biology* 1989;146:87–114.
- [106] Seltzer B, Pandya DN. Afferent cortical connections and architectonics of the superior temporal sulcus and surrounding cortex in the rhesus monkey. *Brain Research* 1978;149:1–24.
- [107] Hietanen JK, Perrett DI. Motion sensitive cells in the macaque superior temporal polysensory area: I. Lack of response to the sight of the monkey's own hand. *Experimental Brain Research* 1993;93:117–28.
- [108] Hietanen JK, Perrett DI. A comparison of visual responses to object- and ego-motion in the macaque superior temporal polysensory area. *Experimental Brain Research* 1996;108:341–5.
- [109] Eslinger P, Damasio A. Severe disturbance of higher cognition after bilateral frontal lobe ablation: patient EVR. *Neurology* 1985;35:1731–41.
- [110] Fletcher PC, Happe F, Frith U, Baker SC, Dolan RJ, Frackowiak RSJ, Frith CD. Other minds in the brain: a functional imaging study of theory of mind in story comprehension. *Cognition* 1995;57:109–28.
- [111] Goel V, Grafman J, Sadato N, Hallett M. Modeling other minds. *NeuroReport* 1995;6:1741–6.
- [112] Stone V, Baron-Cohen S, Knight K. Frontal lobe contributions to theory of mind. *Journal of Cognitive Neuroscience* 1999;10:640–56.
- [113] Rolls ET. Neurons in the cortex of the temporal lobe in the amygdala of the monkey with responses selective for faces. *Human Neurobiology* 1984;2:209–22.
- [114] Rolls ET. Neurophysiology and functions of the primate amygdala. In: Aggleton JP, editor. *The Amygdala: Neurobiological aspects of emotion, memory and mental dysfunction*. New York: Wiley-Liss, 1992, p. 143–66.
- [115] Emery NJ, Amaral DG. The role of the amygdala in primate social cognition. In: Lane RD, Nadel L, editors. *Cognitive Neuroscience of Emotion*. Oxford UK: Oxford University Press (in press).
- [116] Robinson BW, Mishkin M. Ejaculation evoked by stimulation of the preoptic area in monkeys. *Physiology and behaviour* 1966;1:269–72.
- [117] Robinson BW, Mishkin M. Penile erection evoked from forebrain structures in *Macaca mulatta*. *Archives of Neurology* 1968;19:184–98.